

## A Case Report, Pediatric of Hepatoblastoma in Misrata, Libya

Mohamed Abdelhalim Elfagieh<sup>1\*</sup>, Mohamed Ahmed Elfagieh<sup>2</sup> and Mustafa El-Ahmer<sup>3</sup>

<sup>1</sup>Internship Doctor of Faculty of Medicine University, Misrata, Libya

<sup>2</sup>Professor Surgeon of Oncology, General Director of National Cancer Institute, Misrata, Libya

<sup>3</sup>pediatric Surgeon, Managing Director of Pediatric Department of Misrata Medical Center Hospital

### ARTICLE INFO

Received Date: July 20, 2024

Accepted Date: July 28, 2024

Published Date: July 29, 2024

### KEYWORDS

Children; Hepatoblastoma; Liver

**Copyright:** © 2024 Mohamed Abdelhalim Elfagieh et al., Journal of Case Reports: Clinical & Medical. This is an open access article distributed under the Creative Commons Attribution License, which permits unrestricted use, distribution, and reproduction in any medium, provided the original work is properly cited.

**Citation for this article:** Mohamed Abdelhalim Elfagieh, Mohamed Ahmed Elfagieh and Mustafa El-Ahmer. A Case Report, Pediatric of Hepatoblastoma in Misrata, Libya. Journal of Case Reports: Clinical & Medical. 2024; 7(1):176

### Corresponding author:

Mohamed Abdelhalim Elfagieh,  
Internship Doctor of Faculty of  
Medicine University, Misrata, Libya,  
Email: mm.alfegia97@gmail.com

### ABSTRACT

**Introduction:** Hepatoblastoma is primary liver tumor, it's the most common in young children. As a pediatric cancer representing 1% and mainly affect infancy to 5 years of age. And it's the most common malignant in young children, Representing about 79% of all liver tumors in children. May be 100 cases reported per year of hepatoblastoma. Most common site of hepatoblastoma is right lobe of liver and the most common site of metastasis is the lung and the etiology of hepatoblastoma its unknown. **Case Report:** We report the case of A 6- months- old male, admitted to the pediatric surgery department on April 20, 2024. The patient physical exam was abnormal due to liver palpable below costal margin more than 2 cm and diagnostic as hepatoblastoma. **Conclusion:** Hepatoblastoma is uncommon liver cancer in young children, that's representing 1.5 cases per million of population in the world wide, we are early discovered of the hepatoblastoma case and treated surgically.

### INTRODUCTION

Hepatoblastoma is primary liver tumor, it's the most common in young children. As a pediatric cancer representing 1% and mainly affect infancy to about 5 years of age. And it's the most common malignant in young children, Representing about 79% of all liver tumors in children. May be 100 cases reported per year of hepatoblastoma. Most common site of hepatoblastoma is right lobe of liver and the most common site of metastasis is the lung. Hepatoblastoma more common in white young children than black one and its more common in boys than girls. Mainly cause of hepatoblastoma unknown, but there are many risk factors of hepatoblastoma including familial adenomatous polyposis, hemihypertrophy, Beckwith- Wiedemann syndrome, biliary atresia, premature children. and long exposed to hepatitis B as an important risk factor of hepatoblastoma. The following case of hepatoblastoma discussed a 6- months old male, admitted to the pediatric surgery department. Presented with Right Hypochondrium swelling Noticed by his mother associated with fever, loss of feeding, vomiting, loss of weight.

### CASE PRESENTATION

A 6- months- old male, admitted to the pediatric surgery department on April 20, 2024. The patient physical exam was abnormal due to liver palpable below costal margin more than 2 cm. Lab results during this visit included a white blood cell count of {18.29\*10(9)/L}, Hemoglobin {11\*10(9)/L} and platelet count of {531\*10(9) /L}.

Total Bill {0.34\*10(9)/L}, ALT {215\*10(9)/L}, AST {86\*10(9)/L}, ALP {236.6\*10(9)/L} and CRP {162.2\*10(9)/L}; also, viral screen was {HBsAG -ve}, {HCV -ve} and {HIV -ve}. An abdominal ultrasound was performed due to right hypochondrium mass palpable associated with vomiting. Which revealed to hyperechoic vascular was defined mass about 7\*8 cm limited at right lobe of liver. CT scan done and showing Right Hyper genic mass at Right lobe of liver Figure 1.

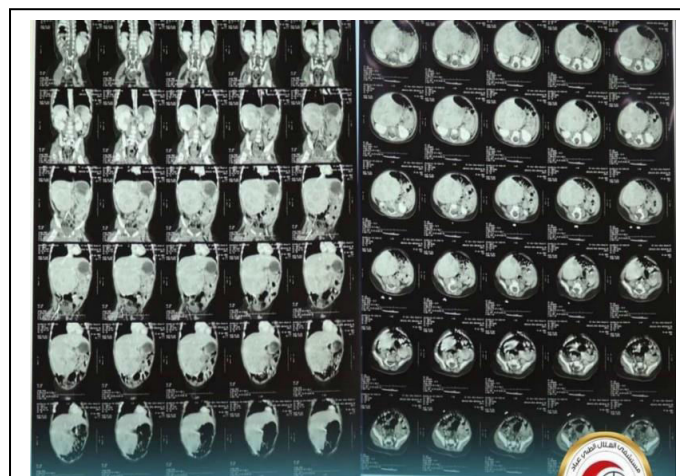


Figure 1: CT scan showing mass at Right lobe of Liver, Figure (1).

Fine Needle Aspiration Cytology (FNAC) done; the finding was consistent small blue round cells tumor indicated to Hepatoblastoma. The patient underwent to right subcostal incision hepatic lesion, occupying right liver segment 6,7,8 and cholecystectomy done due to compressing the tumor on gall bladder and surrounding structure. Resection of the mass with part of normal liver tissue and drain tube inserted in Harrison pores and given 1 unit blood. Histopathology biopsy sent and the results was of right hepatic lobectomy and gall bladder for hepatoblastoma tumor mass: Tumor mass measuring 8cm in greatest diameter in 4 segment or two sections of right lobe. No evidence of perineural invasion, no evidence of lymph vessel invasion, no evidence of blood vessel invasion, no evidence of tissue necrosis. Gleason hepatic capsule free of tumor tissue invasion. Free left medial surgical margin of tumor tissue invasion (The closed margin to tumor tissue 3mm). gall bladder and related lymph node free of tumor tissue metastasis. TNM classification (PRETEXT 2, One LN0, V0, L0, pn0, R0). After operation transfer to an ICU for two days. The patient was conscious, crying and vitally stable. Given claforan 400 mg

1\*3, gentamycin 18mg 1\*2, perfelgan 70 mg 1\*1\*3 Ds, IVF (33ml/hrs. to 45 ml/hrs.) and milk feeding orally after NPO. Then transfer to department with vitally stable and discharged on April 24, 2024 with Augmentin 600mg 1\*2\*5Ds and Paracetamol suppository 125mg 1\*3\*3Ds and the child underwent just on follow-up after six month and ultrasonography showed liver normal and Normal investigation included; (WBC 10.4\*10(9)/L, HGB 12.3\*10(9)/L, PLT 468\*10(9)/L, Glu 102 mg/dl, T-Bil 0.11, D-Bil 0.09\*10(9)/L, ALT 17.1\*10(9)/L, AST 44\*10(9)/L, ALP 397\*10(9)/L, AST/ALT 2.6\*10(9)/L, TP 4.9 g/dl, Urea 8.37 mg/dl, CREA 0.35 mg/dl, IBIL 0.5, ALB 4.7, Glo II 1.9, A/G II 24.8}; and improved progressively.

## CONCLUSION

Hepatoblastoma is uncommon liver cancer in young children, that's representing 1.5 cases per million of population in the world wide, it was difficult to have international staging criteria prior to the PRETEXT staging criteria. We are early discovered of the hepatoblastoma case and was a treated by surgically (partial Hepatectomy) only as a mainly typically treated of hepatoblastoma in pediatric surgical department of Al-Helal Abbad Medical Misrata Hospital. After surgery the child underwent just on follow-up with an improved progressively. The patient didn't have chemotherapy or Radiotherapy after surgery according to histopathology results and TNM classification was PRETEXT 2, one LN0, V0, L0, pn0, R0. But as we know that many clinical trials showing combination. Chemotherapy, Radiotherapy and surgical options and lobectomy, to be the standard of care for this condition mainly of advanced case of hepatoblastoma.

## DISCUSSION

The most of hepatoblastoma cases presented with palpable enlarged abdominal mass. The right lobe involved commonly than left lobe and both affected in 20-30% of cases and multicentric in 15%. Hepatoblastoma may be associated with uncommon symptoms as anorexia, weight loss and pain. Lab and imaging investigation done. The biopsy it's important to confirm the diagnosis of hepatoblastoma and PRETEXT staging was; PRETEXT 2, one LN0, V0, L0, pn0, R0. And we used PRETEXT stages to help us in the treatment:

- Stage I: Complete surgical resection.
- Stage IIa: residual intrahepatic microscopic disease,

Complete macroscopic surgical resection.

- Stage IIb: residual extrahepatic microscopic disease, Complete macroscopic surgical resection.
- Stage IIIa: Incomplete surgical resection with macroscopic residual and/or significant tumor spill and/or positive lymph node disease.
- Stage IIIb: Tumor not resectable.
- Stage Iva: Distant metastatic disease, primary tumor completely resected.
- Stage IVb: Distant metastatic disease, primary tumor incompletely resected.

The etiology of hepatoblastoma unknown. And the metastasis occurred in 10-20% of patients. The common site of metastasis is lung, and other sites of metastasis is brain and bone as a rare site of metastasis. The standard care in patient with hepatoblastoma is surgically (Lobectomy) as an initial treatment and achieve long- term disease free survival by eradicated all areas of disease. But in some cases, underwent for liver transplantation due to non resectable tumors or chemotherapy resistance. Non resectable tumors associated with large in size, excessive bleeding, involvement both the right and left lobe, extended to major hepatic vein or IVC; or presented as diffuse multifocal disease. We depended mainly on surgical treatment as an initial therapy and the patient followed for 6 months with improved progressively. And there was some case report studies also used a surgical treatment in early stage of hepatoblastoma case as a most care treatment and they had an improved progressively. While surgical resection provides the best outcome and is the primary goal of the therapy; Congenital Hepatoblastoma Tumor (CHT) has implied a multimodal approach to treatment from surgery alone [1], Although one of the cases did not respond to chemotherapy very well a complete resection was achieved and therefore a disease-free survival of 15 years [2], Complete surgery is the mainstay of therapy in hepatoblastoma [3], The mainstay of the treatment is complete surgical removal of the mass [4] and some other case report studies used the combination treatment of chemotherapy and surgery in late staging of hepatoblastoma case. Combining surgery and chemotherapy could increase the percentage of patents with hepatoblastoma [5], In this case, the onset of hepatoblastoma was early, and the tumor grew rapidly, resulting in an obvious compression

effect.

Chemotherapy was started early after birth, and the curative effect was satisfactory [6], Management of CHs generally involve complete surgical resection of the tumor, chemotherapy and possible liver [7], Chemotherapy treatment depends on standard versus high-risk patients as well as early versus delayed tumor resection. Typically, 5 to 6 chemotherapy treatments are standard for high-risk patients. Cisplatin is the most active single agent used to treat hepatoblastoma [8].

## FUNDING

None.

## ETHICAL APPROVAL

None required.

## CONSENT

Informed written consent was taken from the patient's parents.

## REFERENCES

1. Priya C, Varshini C and Biswakumar B. (2019). Hepatoblastoma- An Unusual Presentation: A Case Report, Department of Paediatrics, Indira Child Care, Chennai, India. J Clin Case Rep. 9: 1240.
2. Antoine El Asmar, Ziad El Rassi. (2016). Hepatoblastoma in childhood, long term survival achieved: 2 case reports and literature review. Int J Surg Case Rep. 21: 55-58.
3. Daniela Iacob, Alexandru Șerban, Otilia Fufezan, Radu Badea, Cornel Iancu, et al. (2010). Mixed hepatoblastoma in child. Case report. Med Ultrason. 12: 157-162.
4. Guntvanti Rathod, Goswami SS, Rahul Goyal and Shweta Mehta. (2014). Paediatric Hepatoblastoma in one year old female A case report. Int J Curr Microbiol App. Sci. 3: 829-835.
5. Hanae Bahari, Hanane Hajaj, Hind Zahiri, Ayyad Ghanam, Abdeladim Babakhouya, et al. (2024). Pediatric Hepatoblastoma: A Case Report and Review of the Literature. Open Journal of Pediatrics. 14: 2.
6. Zheng Yan, Wei Bai, Li Li, Shuo Li, Ying Hua, et al. Case Report of Congenital Hepatoblastoma With the Onset at 30-Weeks' Gestation. Front Pediatr. 2022; 10: 905089.
7. Gloria Ha Young Yoo, Veronica Mugarab-Samedi, Gregory Hansen, Grant Miller, Laurence Givelichian, et al. (2020). Rare cause of emergency in the first week of life: congenital hepatoblastoma (case report). Oxf Med Case Reports. 2020 Feb; 2020(2): omaa002.
8. Anthony D DeRenzi DO, Audrey Bowen MD. (2023). A Case Report and a Review of Pediatric Hepatoblastoma, DeRenzi and Bowen. HCA Healthcare Journal of Medicine. 4: 377-382.