

## “Tips, Trics and Long-Term Results of the Treatment of Trapezometacarpal Joint Osteoarthritis with Total Arthroplasty”

Miguel Martín-Ferrero\*, Clarisa Simón Pérez, Belen García Medrano, Hector Aguado Hernández, Oscar Martín Cal and Aurelio Vega Castrillo

Department of Orthopaedic and Trauma Surgery, University of Valladolid, Spain

### ARTICLE INFO

#### Article history:

Received: 11 May 2017

Accepted: 06 July 2017

Published: 12 July 2017

#### Keywords:

Arthroplasty;

TMCJ OA;

FTS;

MCPJ

**Copyright:** © 2017 Martín-Ferrero M et al.,

Ann Orthop Trauma Rehabil

This is an open access article distributed under the Creative Commons Attribution License, which permits unrestricted use, distribution, and reproduction in any medium, provided the original work is properly cited.

**Citation this article:** Martín-Ferrero M, Simón Pérez C, García Medrano B, Aguado-Hernández H, Martín Cal O. “Tips, Trics and Long-Term Results of the Treatment of Trapezometacarpal Joint Osteoarthritis with Total Arthroplasty”. Ann Orthop Trauma Rehabil. 2017; 1(1):114.

#### Correspondence:

**Miguel Martín-Ferrero,**

Head of Orthopaedic and Trauma Surgery at Hospital University Clinic and Professor at Medical School, University of Valladolid, Spain,  
Email: ferrero@cir.uva.es

### ABSTRACT

Until a few years ago it was not given any definitive therapeutic solution to the Trapezio-metacarpal joint osteoarthritis (TMCJ OA). The first surgical solutions were simple and consisted of removal of the trapeze (trapezectomy). Afterwards, it came some procedures based in ligamentous reconstruction and tendon interposition (LRTI); these, use different neighbourhood tendons trying to improve the length and strength of the thumb that diminish with trapezectomy.

Nowadays, there are exists numerous and specific surgical techniques for the treatment TMCJ OA; the choice of one or the other technique is determined, among other factors, by the patient's age, tasks performed by the hand in daily activities, radiographic stage of disease and the surgeon's experience on each particular technique.

In our daily clinical practice we see frequently active patients (women between 50 and 60 years of age) with Eaton and Littler grade III of TMCJ OA, whose OA affect only the TMCJ, being healthy the other four peritrapezium joints. Consequently, we do not feel comfortable performing trapezectomy on these patients, and therefore we decided the total arthroplasties, that respect the healthy joints and gets more strength for the thumb.

There are numerous models of prostheses, the first to be used were these of De la Caffinière, in 1973, they allowed preserve mobility, grip strength and clamp, and they prevented the shortening of the first metacarpal, with a more quickly recovery than trapezectomy. As they were cemented and constrained, they had some disadvantages like loosening, dislocations, and as any other prosthesis, mechanical failure with time.

The TMCJ total arthroplasty of Arpe® type, was designed in 1991 by J.J. Comtet and the author described it as a spherical prosthesis (ball and socket), direct, uncemented and not constrained. The primary intraosseous fixation is ensured by an anatomical design of the components and the press-fit effect. The secondary fixation is achieved by the coating of hydroxyapatite of the cup and the metacarpal shaft. This type of arthroplasty seem to us be the most evolved of all by the features and changes made in the classic De la Caffinière to allow a long survival. This prosthesis, from our point of view, was

the one that met most of the rules that could require a good arthroplasty for TMCJ, and therefore we started to put it in 1999.

Our aim in this paper is to expose the indications for surgery, detailed surgical technique and long-term results of these prostheses.

## Introduction

Until a few years ago it was not given any definitive therapeutic solution to the Trapezio-metacarpal joint osteoarthritis (TMCJ OA) and its treatment was symptomatic by immobilization and analgesia. It was from the fifties when they began to appear surgical solutions that suppress pain and improve function of the thumb.

The first surgical solutions were simple and consisted of removal of the trapeze [1]. Afterwards, an anchovy made with the FCRL tendon, which improved functionality, replaced the trapeze [2]. Then, they came some procedures based in ligament reconstruction and tendon interposition (LRTI): Burton-Pellegrini [3,4], Zancolli [5], Schecker [6], those use different neighbourhood tendon plasties trying to keep the length and strength of the thumb.

In parallel was performed, and is still performed on patients with hard works, TMCJ arthrodesis, managing to keep the length of the thumb and improve strength, but with the problems of reducing the mobility of the thumb and the onset osteoarthritis STTJ with the years, as there is an overload of this joint [7].

Swanson proposed the use of silicone spacers, which prevented the proximal migration of the metacarpal, and favoured a rapid recovery and a good thumb grip. But numerous cases of subluxation, breakage and adverse reactions to silicone were published [8].

Nowadays, there are exists numerous and specific surgical techniques for the treatment TMCJ OA; the choice of one or the other technique is determined, among other factors, by the patient's age, tasks performed by the hand in their daily activities, radiographic stage of disease and the surgeon's experience on each particular technique [4,9].

The Eaton and Littler Classification was destined to make a rational choice between different therapeutic methods of treatment, according to the radiological developmental stages of TMCJ OA, and is the most accepted by authors [10].

Total joint replacements are being used in this pathology for many years. There are numerous models, the first to be used were De la Caffinière, in 1973, which allowed preserve mobility, grip strength and clamp and prevented the shortening of the first metacarpal with a very quickly recovery [11]. They have some disadvantages of loosening, in the cement-bone interface, dislocations, and as any other prosthesis, mechanical failure with time [12].

Cooney et al [13] developed a second type of cemented total prosthesis. In this model, components are inverted the cup and head. Trapezium component is formed by a metal implant with a pedestal sphere ends protruding from the bone surface and the metacarpal implant consists of a rod polyethylene ending in a cup. With this implant observed a lot of heterotopic bone formation (36%), affecting negatively the final result report.

The use of prostheses generally requires the presence of a good bone quality, especially in the trapeze that is the seating of the cup of the implant. The presence of STTJ OA or in the MCPJ requiring arthrodesis is associated with early component loosening in cemented prosthesis, and is a contraindication for placing a prosthesis [14].

The ideal implant should allow functional joint reconstruction, must be biocompatible, with a long period of survival, uncemented to avoid the common problems of loosening at the interface cement-bone and should not be the last possible therapeutic solution in case of failure [15].

In our daily clinical practice we see frequently active patients (women between 50 and 60 years of age) with Eaton and Littler grade III of TMCJ OA. We did not feel comfortable performing trapezectomy on these patients whose OA affected only the TMCJ joint, Being healthy the other four peritrapezium joints, and therefore we decided the total arthroplasty.

The prosthesis in which had been published more abundant and longer history papers was the De la Caffinere [13,16-18]. These studies showed that functional results appear to be durable over time and in a high percentage, maintaining the correct position. However, this prosthesis had two peculiarities that did not convince us completely: one is that it is attached to the bone with cement, and the other that is constrained, both of them facilitate the prosthetic early loosening.

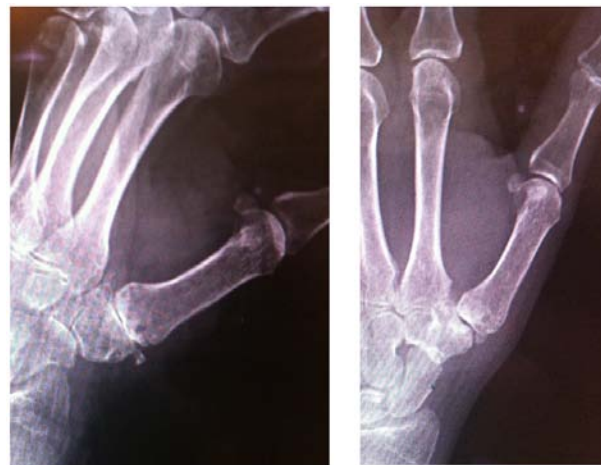The TMCJ total arthroplasty of Arpe® type, was designed in 1991 by J.J. Comtet and the author described it as a spherical prosthesis (ball and socket), direct, uncemented and not constrained. The primary intraosseous fixation is ensured by an anatomical design of the components and the press-fit effect. The secondary fixation is achieved by the coating of hydroxyapatite of the cup and the metacarpal shaft. This type of arthroplasty seem to us be the most evolved of all by the features and changes made in the classic De la Caffinere to allow a long term survival [19,20]. This prosthesis, from our point of view, was the one that met most of the rules that could require a good arthroplasty for TMCJ, and therefore started to put it in 1999.

### Indications for Surgery

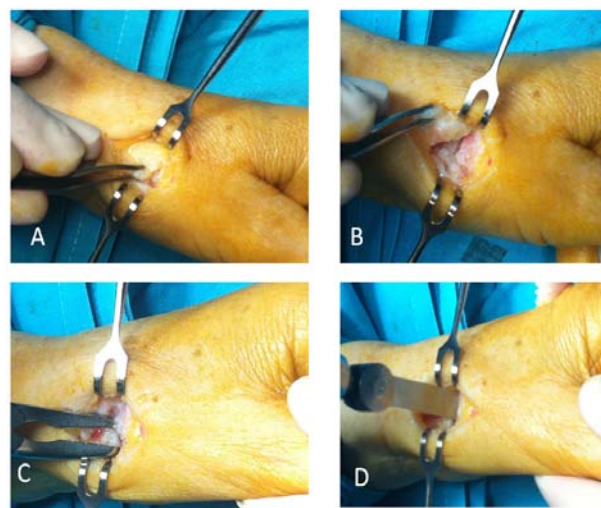
The ideal indication of the prosthesis is trapezometacarpal grade III Eaton-Litler, arthritis in patients with good bone quality and functional demands that will not be heavy manual labor. The existence of trapezo-metacarpal subluxation does not contraindicate the implant. The STTJ OA moderate if the joint is observed stable (there is no radial subluxation of the trapezium) does not contraindicate the implant (Figure 1).

The ideal age for prosthesis is around 60 years, because in younger patients, although our results over 10 years are promising, is not yet available abundant data of this prosthesis. In patients older than 75 years, bone quality is lower by osteoporosis and fixation of the implant goes down and there is some subsidence of the prosthetic components.

Ulnar laxity of the MCPJ is sometimes associated with stiffness of the first metacarpal in adduction, if we decide to place an implant it must be released the metacarpal. At the same time that we implant the prosthesis is necessary treating ulnar ligamentous laxity by ligamentous plasty and not a mere internal capsular fold.



**Figure 1:** Woman, 61 y old, TMCJ OA IV of Eaton, with some affection of the STTJ associated, but without any instability of this last joint.

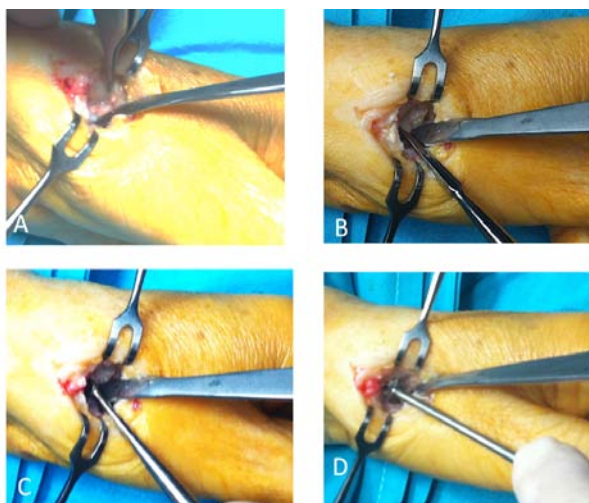


**Figure 2:** A. Incision; B. Capsular flap; C. Resection of loose bodies; D. Osteotomy of the base of the metacarpal.

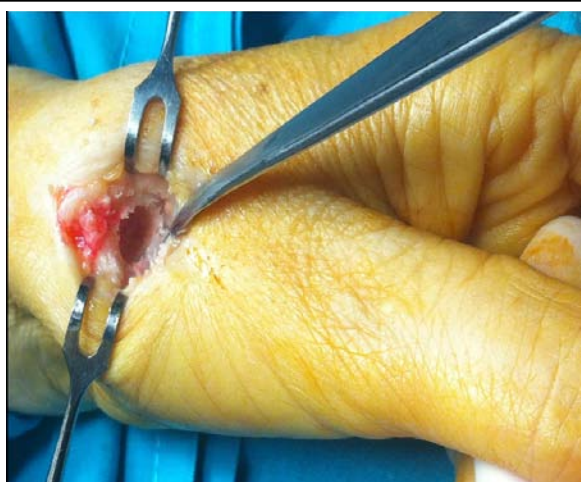
Hyperextension of the MP joint less than 20° is no problem, and usually corrects when the implant is placed because the length of the column of thumb is recovered. However, if it is greater than 30°, it must be corrected at the time of implant placement, because it will have



subluxation of components. You can make a radial sesamoid arthrodesis to the metacarpal head, or even arthrodesis of the MCPJ if there is arthritis associated. We have not placed prosthesis in patients with rheumatoid arthritis or other inflammatory arthritides, for obvious reasons of bone quality. Finally, do not indicate the prosthesis in cases of neuropathic arthropathy or paralysis incompatible with TMCJ function, as in any other prostheses.



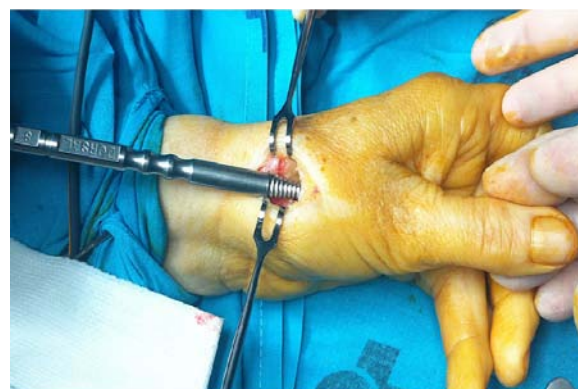**Figure 3:** A. Resection of the radial osteophyte of the trapeze; B. Search of the center of the distal articular surface of the trapezium and the beginning of the hole with a punch; C. Enlarging of the hole with curette from 4/0 to 0; D. Ending of the hole for the cup with the prosthetic reamer.



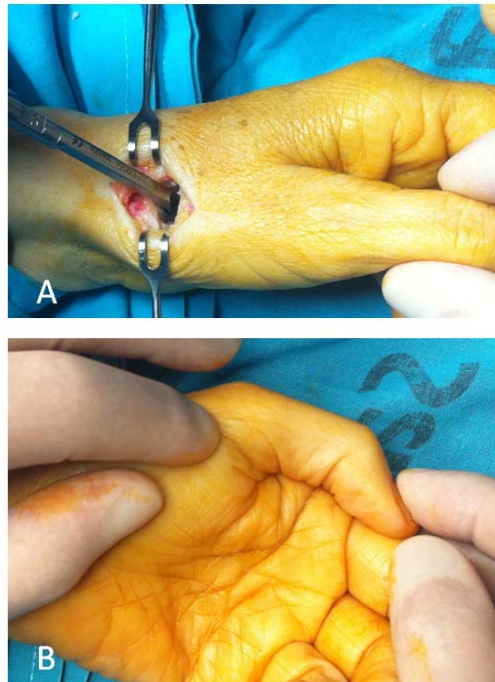
**Figure 4:** Hole in the centre of trapeze to placed the cup.

## Surgical Technique

The TMCJ arthroplasty Arpe® type, is a ball and socket modular and versatile, with four different sizes prosthesis stem that is placed in the metacarpal and two dome sizes placed on the trapeze. The neck can be straight or bent. The friction torque is metal-polyethylene. And the dome is made of titanium alloy coated with hydroxyapatite [19].



**Figure 5:** Milling of medullary canal of the metacarpal bone, appreciate the mark of the rasp that must be in the same plane that the thumb nail.



**Figure 6:** A. Components of proof are placed and are tested for stability. B. Way to know the thumb length.

The designer of the prosthesis recommended the antero-external access in surgical technique, and so we made the first 100 implants. Then, we changed to the postero-external (dorso-radial) approach for several reasons: better access to the distal surface of the trapezium in its entirety, better possibilities for alignment of the stem, which is what we describe below in tips and tricks.

### 1. Current technique [18]

The technique is performed in Ambulatory Surgery, under brachial plexus anesthesia and ischemia in the proximal arm, the usual doses is 2 grs. of cefazolin prior to the intervention.

We use a postero-lateral (dorso-radial) approach by a dorsal longitudinal incision of about 4 to 5 cm. following the extensor tendons of the first compartment, centred on the TMCJ. In this area there are very sparse branches of the radial nerve, as the two main branches are one dorsal and palmar the other to incision. However, small sensory branches that may exist must be located and protected.

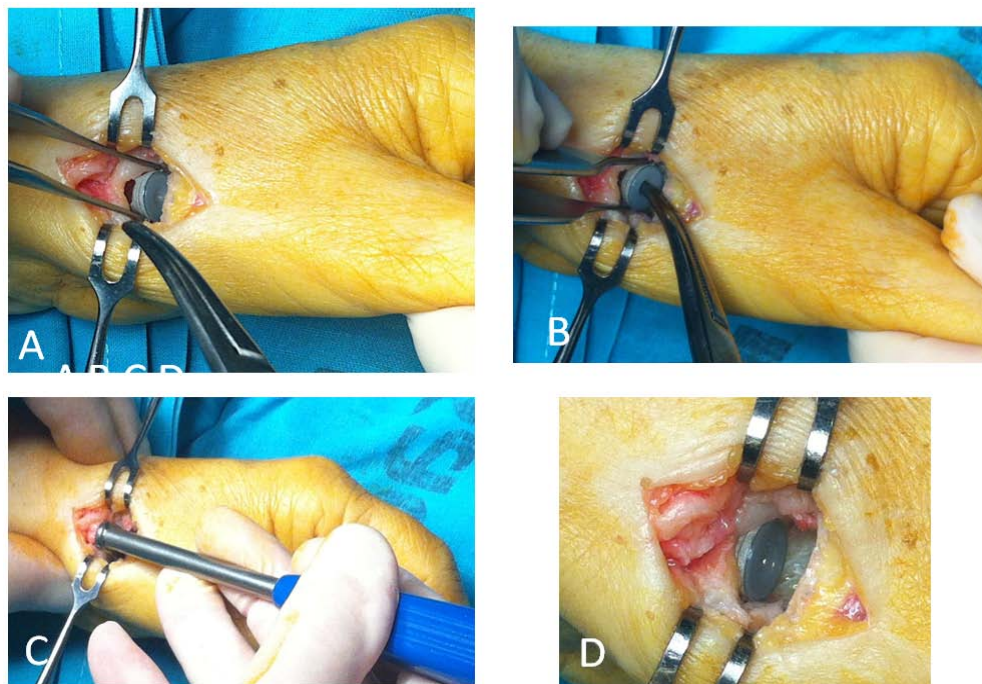
The EPB tendon is dissected and dorsal retracted, APL remains palmar (Figure 1A). In cases of TMCJ OA with large dorsal subluxation of the metacarpal base we have dissected the entire course of the dorsal branch of the radial artery to prevent injury. Subsequently, a capsular L-shaped incision is done with the transverse branch of the L located 5 mm. proximal to the metacarpal base, extending from side to side. The longitudinal branch begins at the radial border of the metacarpal base, joining the transverse incision and directed proximally by the edge of the APL tendon and extends along the entire length of the trapezium (Figure 1B). After, we dissect the capsule separating it from the deep structures, then the TMCJ is exposed in its entirety and the capsular flap is retracted back (Figure 1C). The APL tendon insertion is carefully respected. This flap is carefully preserved during surgery to suture then reconstructing the original capsule.

A frontal saw is used to remove the proximal base of the thumb metacarpal, beginning dorsally in the proximal part of the base, with an orientation perpendicular to the axis of bone in the radio-ulnar sense and an angle of 20° in dorsal-palmar sense. Thus,

in the dorsal side resection is minimal (3-4 mm.), and a major resection (6-8 mm) is made on the palm side (Figure 1D). Then it is removed the proximal base fragment together with periarticular fibrosis, what suppose ligament release, and provide us with more workspace. At this point, longitudinal traction is applied to better expose and clean the surgical space. We separate the metacarpal to the palm with a small Hoffman to obtain a complete view of the trapezium in all its distal face. A ronger is use to remove the marginal osteophytes (it is specially important takes away the osteophyte that protrudes on the distal ulnar side of the trapeze to avoid shock with the metacarpal base which can dislocate the prosthesis) (Figure 2A). The wider osteotomy of the metacarpal allows easy mobilization to access and work on the distal articular surface of the trapezium, where the prosthetic dome will stay.

As the entire surface of the distal trapezoid is exposed, we can pinpoint easily the geometric centre of the articular surface, and at this point a perforation with a punch is made (Figure 2B). This will be the centre of the cavity that will house the cup. The hole is increased progressively with curettes (from 4/0 to 0), and is then end with the manual reamer that provides the instrumental for the prosthesis (Figure 2C,D); we never used motorized drills, to create the hole within the trapezium, because it is more difficult to control exactly, and could provoke bone necrosis (Figure 4).

The medullary canal of the first metacarpal is penetrated with a punch first, increasing progressively the size with rasp until cortical bone (it should be adjusted to the size of the medullary cavity to avoid posterior subsidence of the stem), the rotational orientation is achieved easily with the dorsal mark of the rasp run parallel to the plane of the nail (Figure 5). Stem proof is placed, and put on him neck that is considered the right size, then is placed the proof cup also, the components are reduced, and the length of thumb is checked, mobility and stability of arthroplasty (Figure 6A). The length of the thumb is calculated as follows: the thumb is extended in retroposition and, so placed, the palmar creases of the IP must match the thenar palmar crease line of the hand (Figure 6B).



**Figure 7:** Placing the cup: A. Reception and presented with a clip; B. Pressed at the beginning with cocher clamp; C. Impaction with the specific instruments of the prosthesis; D. cup placed in final position.

The definitive implant is placed; we begin by the cup, which is placed generally parallel to distal surface of the trapeze. To put the definitive cup at first we help with forceps Kocher and once centred and with the desired direction (Figure 7A,B), we impact it with the provided instruments in the prosthesis, while we are impacting, the assistant must embrace with fingers the trapeze, just to avoid problems of rupture or burst (Figure 7C,D). Then, we put the stem, whose dorsal marks have to be parallel to the thumbnail (Figure 8A,B). Again checking the length with neck test. Finally, we put the definitive neck, and we test stability and mobility of the implant, subjecting him to stress in all directions before closing (Figure 9,10). Ending with the closure of the capsular flap, suction drain and the skin closure with suture resorbable continuous, because during the three-week immobilization must not to be performed cures.

## 2. Associated procedures

Many patients with TMCJ OA have associated pathologies that we use to solved at the time of the prosthetic surgery: carpal tunnel (CT), flexors tendon synovitis (FTS) in the thumb or other finger, and de Quervain disease, are among the most frequent.

The carpal tunnel release, is done at the same time but by another approach, who was described by Simonetta [21]. Incision is located parallel to the thenar crease of the palm, 5 mm by the ulnar side.

When there exist FTS, we perform tenolysis. On the thumb is made percutaneous with a needle, and the other fingers usually open.

Before closing the incision, the first extensor compartment is reviewed. If stenosis or double compartmentalization is observed, we open the first extensor compartment.

When other surgeries associated with the prosthesis are made, the last to be closed is the incision by which has been placed the prosthesis; this is to prevent dislocation of the components while the other procedures are being performed.

## 3. Postoperative care

After surgery, the column of the thumb is immobilized with a short palmar splint plaster, well padded for 3 weeks. While the bandage is applied it should not pull the thumb to prevent dislocation of the prosthesis. The dressing is not removed to cure unless there are clear



symptoms of pain or swelling. Generally postoperative pain is mild, so it goes away with regular analgesia.

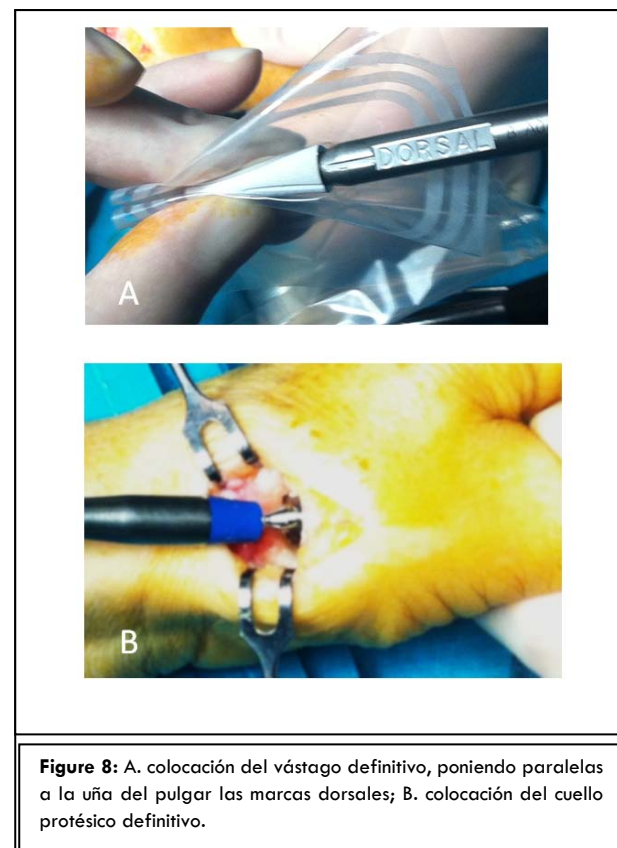
Whenever there are reasonable doubts during the procedure, about future stability of the implant, Xray is done during the process; otherwise, the first X-ray control is performed when the immobilization is removed (Figure 11). At this time, is prescribed exercises: flexion and extension, abduction and adduction, and opposition of the thumb. In half times, the patient gets full mobility without having to go to rehabilitation department; patients are send there if in the first review at two weeks have not recovered the mobility. The normal load of thumb is allowed at 6 or 7 weeks after surgery. Later, we perform annual periodic reviews the first two years after surgery, and then biannual.

### Results

Our studies [16,17,22,23] and others [11,13,15,22] have demonstrated clearly that ball and socket total arthroplasties have good short-term results in terms of aesthetic appearance and length of the thumb. The results in mobility, grip and pinch strength, fine clip between thumb and index, pain relief and satisfaction of patients are also much better than in the trapeziectomy. Another advantage of this technique is the rapid recovery of these patients (6-8 weeks), with minimal postoperative pain.

The question about survival and functionality of this implant long-term, is answered because each time there are more studies that demonstrate a high survival index with the implant of De la Caffiniere [12,25-27], being until 26 years of follow-up in the study of Johnston et al [2]. And also, our posterior long-term studies, published in 2014 the first [16], including our 69 consecutive first implants of Arpe, with functional survival Kaplan-Meier to long-term (over 10 years) of 93.9%, and the second [23] in 2015, including 116 consecutive implants of Arpe, with survival at more than 10 years of 94,1% (very similar to previous one), have demonstrated that these arthroplasties have a durability quite close to that of the hip, which is the gold standard in orthopaedics (Figure 12). We strongly recommend that you see these

publications, where you can find details of the methods of clinical and radiographic review of all the patients.

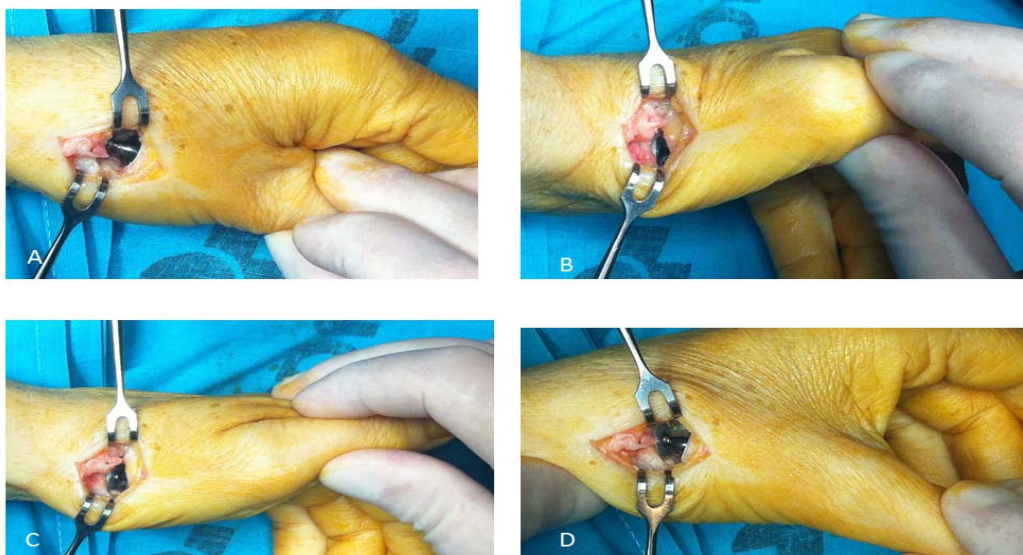


### 1. Perioperative complications

The problem in the first surgeries, which had been done by antero-external approach of the original technique, was the small surgical space that you have to work with ease, making it difficult to correct positioning of the implant. Therefore, we changed to pure dorsal approach.

Another problem some of the first patients was that the cup rested too deep, since the distal trapezium resected in osteotomy reduces the size of the bone and also, the subchondral bone is removed, therefore the implant is only be supported by cancellous bone. That's why we decided not to do distal osteotomy of the trapezium.

In a patient that occurred a full fracture of the trapeze during cup placement, we solved by placing a wire cerclage, which later failed. In three patients with trapeze minor cracks, which did not cause alterations in the stability of the acetabulum, in these cases immobilization has been prolonged a week more, and there have been no changes in the future osteo-integration of the cup.



**Figure 9:** Reduction of components of the prosthesis and impingement-stability tests with stress in flexion (A), extension/ radial abduction (B), adduction/retroposition (C) and volar abduction (D) of the trapezometacarpal joint.

There have been no major fractures of metacarpal that alter the stability of the prosthetic stem. In two cases there have been small cracks, which have not required any associated treatment more that prolong for a week more the immobilization.

In the number 8 of the series of our prostheses, was made a false passage in the metacarpal, leaving the stem tip protruding a few mm. in the dorsal side. The prosthesis remains functional at the present time, at 11 years of evolution.

We have not observed significant thumb malrotations because the reference of the nail when the stem of the prosthesis is placed is very easy to follow.

Also at the beginning, we had the tendency of leaving too tight prostheses, for fear of dislocation, very soon we realized that the ball and socket prostheses worked better when they are not uptight and, if the components are well oriented, even without tension are very stable.

Most perioperative complications occurred in the first 30 implants placed, therefore, it is important to stress that prostheses have a learning curve.

## 2. Soft tissue problem

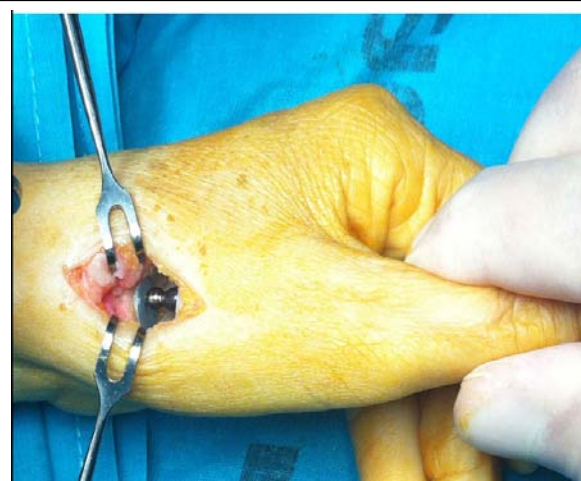Ten per cent of the patients complained of paresthesias or dysesthesias of the thumb due to surgery, but only in two patients discomfort persist over time, neither of the two patients who have suffered regional pain syndrome type I had sequels at 10 years.

There have been not deep infections. There were four cases (5,7%) of intolerance to stitches.

## Tips and Tricks After 17 years of Experience working with these Arthroplasties

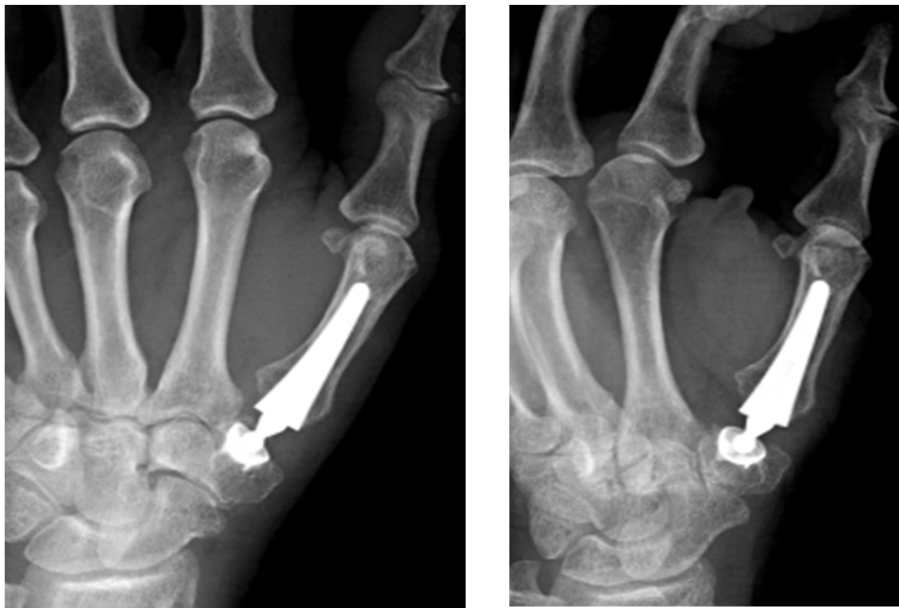### 1. Implant decision

In the seventies appeared total prosthetic arthroplasty for the treatment of TMCJ OA, divided according to their mechanical principle into two broad groups: ball joint arthroplasties type, spherical or ball and socket, and arthroplasties coating surface [20].



**Figure 10:** Tension stress test for longitudinal stability.





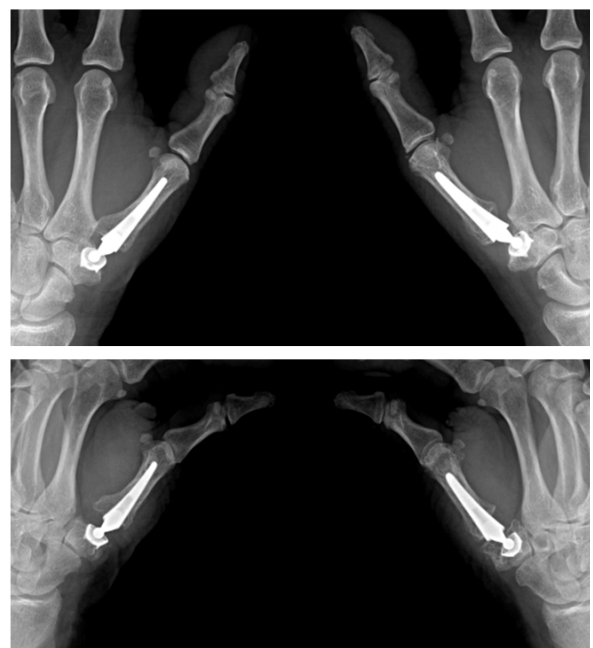
**Figure 11:** Postop. X-ray control. Appreciate that the major resection of the neck provides more space between the base of the first metacarpal and the base of the second metacarpal and the trapezium, avoiding bone impingement, which in some movements could cause dislocation of the prosthesis.

Since then it has been observed that total prostheses have better functionality than trapeziectomy and arthrodesis; less painful postoperative surgery, and shorter period of recovery. The long-term durability, is still supported by few jobs [16,23].

When we started in the total arthroplasties, we take as reference the prosthesis of De la Caffinière [28], since there were multiple publications on it with good long-term outcomes [2,12,25-27,29]. The arthroplasty of De la Caffinière managed to keep the length and appearance of the thumb, the precision of movement and strength of the pinch; however, it was cemented prostheses and constrained, and for these two reasons it had the disadvantage of loose over time. Its author recommend select the patient correctly and make a systematic and precise surgical technique to achieve good results [28].

In 1991 Comtet has designed a spherical prosthesis who has called Arpe, with two advantages over previous De La Caffinière: a) it is coated hydroxyapatite (uncemented) and b) is unconstrained. With these two conditions was to be expected that will improve the long-term outcome in respect to its loosening, but it could dislocate the components because they are not constrained [19].

In 1999, we decided to place in the TMCJ OA the prostheses of Arpe, with the aim of improving the outcome of this disease. Before, we had been operating many patients on this condition for several years, with other different surgical procedures (trapeziectomy, LRTI, arthrodesis, etc.).



**Figure 12:** Woman. 71 y. Old. Bilateral Arpe prostheses. Left: 12 y. Follow-up. Right: 11 y. Follow-up.

At first we used the inclusion criteria for arthroplasties recommended by De la Caffinere [12], which were mainly: a) placement in TMCJ OA types III and IV of the classification of Eaton- Littler; b) existence of a good bone quality on the trapeze, and c) patients with moderate manual activity. We discuss in detail the indications that have been defined by experience in the next lines [18].

## **2. Indication for surgery and patients age**

The ideal age, in our opinion, to indicate the prosthetics in the TMCJ OA is between 50 and 65 years. It is a working age in which patients claim to have good mobility, aesthetics and functionality in the thumb, and they can get with implants. Below 50 years of age must prevent the patient about the possible wear or failure, because there are still not many studies on long-term results. Above 75 years of age, bone quality is not optimal and the patient does not demand much functionality to the thumb as when younger.

## **3. Indication for surgery and physical activities**

There are a number of physical activities that in the past were not considered strong, but in today's society are the strongest, such as housewife, cleaning, cooking, hairdressing, and assembly lines. In these patients is where we placed most of the arthroplasties, therefore most of the implants are placed in today's hard works, and still show good long-term results. The group of patients with heavy work or manual activities that can hit on the thumb, or that could force on the thumb unexpectedly and fortuitously, are where the arthroplasty is contraindicated [16,22]. This group is becoming smaller in today's society.

## **4. Indication for surgery and bone quality**

The poor bone quality and loss of function in multiple joints in rheumatoid arthritis over time, causes these patients would not be suitable candidates for this type of prosthesis. Throughout the series there is only a rheumatic patient, in a woman who was very young. Patients with arthropathy of the TMCJ of neuropathic or paralytic type are not an indication, the same as for any type of prostheses in other locations.

## **5. Indication for surgery and the contralateral hand**

When a patient comes to us for to treat a TMCJ OA of the hand and has been previously operated of the contralateral hand with a trapeziectomy or LRTI, the first decision would be another trapeziectomy, not prosthesis, because it would occur a difference of length between both thumbs [16,23]. There are some exceptions, such as patients between 50 and 60 years with very good bone quality, and good trapeze size for the implants surgery, in which surgeons who do not use prostheses had done the first surgery.

In some patients of our series, with bilateral TMCJ OA affectation, and a hard work, it has been performed an arthrothesis in the dominant hand and a prosthesis in the nondominant side, to preserve complete mobility in one hand.

## **6. The surgical technic variations generated by experience**

Our experience with the use of these implants has allowed us to make technical changes, both in the surgical approach, as in surgical technique, which improve placement, positioning and adjustment of implants, and consequently will improve the outcome long term.

The Osteotomy of the metacarpal we were doing at first, who was the recommended by original author, seemed to us insufficient because in some X-ray controls were in contact the base of the first metacarpal with the trapeze or with the base of the second metacarpal, which suppose a risk of dislocation. So we started make a more wider resection of the metacarpal base, what in addition to avoid impingement, allow us to mobilize more fully the metacarpal bone, and dispose of more room and better manage instruments to place the prosthetic components more easily [18]. Furthermore, we have observed that the extension of the metacarpal base resection does not have consequences in the future outcome for the metacarpal stem, even long-term.

In the original surgical technique, the author recommended equally a limited resection of the distal articular surface of the trapezium, and on the resting surface, the point where it begins to make the hole for the cup had been calculated with a special punch placed on the stem proof. With this device, pressing axially on

the thumb of the patient, is marked the point where should be the centre of the hole for prosthetic cup [19]. This manoeuvre was totally inaccurate because according the position of the thumb it could vary a lot the point of the mark. Therefore we soon abandoned this practice. As we have more space due to the wide resection of the metacarpal base, we can visualize fully the distal articular surface of the trapezium and this allows us easily, the search for its geometric centre to start there the hole for the placement of the prosthetic cup [18].

We also stopped the osteotomy of the trapezium, because we believe that is very important preserve their bone mass, and because the subchondral bone must be respected because it is the ideal element for resting and supporting the prosthetic cup. Therefore, in the actual technique the whole trapeze is left, only peripheral osteophytes are resected because they can alter the real dimensions of the distal articular surface of the trapeze and hinder the perception of its centre [18].

We use the bend neck, instead of the straight one, because we thought that during the opposition, the bend converts the pure rotary motion, that would have the metacarpal with the straight placed, in an ellipsoidal circumduction movement, which is closer to the original movement of the TMCJ. In addition, the bend neck, aesthetically enhances the appearance of the thumb, because it makes it protrudes a little more the metacarpal base.

In respect to postoperative immobilization splint, we have reduced the size until it has become in one that just immobilizes the thumb column, freeing the joints not involved in the prosthesis (IPJ and WJ). It has been used in a lot of patients and have not existed dislocations so we consider it enough.

Half of patients have not required postoperative physiotherapy in a rehabilitation department for functional recovery, and they recover on their own with a learning program of exercises taught by us.

#### **7. Associated influence of the STTJ alterations**

Throughout these years we have realized that there are certain added difficulties in the evolution of the implant in some patients with TMCJ OA grade IV of Eaton.

Patients with osteoarthritis of the STTJ mild to moderate with the line formed by the joint and the axis of the forearm quite perpendicular (less than 50 °) have no contraindication for arthroplasty and they will develop well with time. Contrary, patients with STTJ OA severe, with dysplasia of the trapeze or trapezes small and subluxation of the STTJ (subluxed trapeze that protrudes scaphoid by the radial side) are not good candidates for implant, due to technical difficulty, and also that subluxed trapeze in which the cup will be placed is suffering the pressure constant and subluxes further with time. Therefore, we advise not to place an arthroplasty in these last patients.

#### **8. Associated influence of the MCPJ alterations**

Spontaneous evolution of some patients, who have ulnar laxity of the MCPJ at the time of placing the prosthesis, is continue with the metacarpal adduction they had previously and the thumb works with the lax MCPJ. Over the years the prosthetic components will dispose in angle with apex in the radial direction, then it appearing subluxation of the head. Therefore, the existence of ulnar laxity of MCPJ is not a contraindication for the arthroplasty, but it must be treated effectively at the same moment the prosthesis is placed, making a ligamentoplasty and not a simple capsular fold.

The slight hyperextension of the MCPJ, not exceeding 20° is usually corrected by placing arthroplasty, because the thumb gets some more length, and will be balanced de MCPJ. Sometimes, a simple gesture can help to control the MCPJ hyperextension, if it is some more marked, is the dorsal transposition the APL at the base of the metacarpal at the time we close the capsule. If the MCPJ hyperextension exceeds 30°, and we make a total arthroplasty, the metacarpal is flexed and with time, the prosthetic components will be put angled with the apex in dorsal direction, and the head could sublux or even dislocate. To avoid this disturbance, it is necessary making a treatment of this deformity at the same time the prosthesis is placed. The treatment consists in making a fusion of the sesamoid of the radial side of the MCPJ to the metacarpal head. This intervention is relatively simple, only adds a few more minutes to surgery, and prevents hyperextension of the MCPJ [22].



In patients with severe and fixed hyperextension of the MCPJ, it can be made an arthrodesis. Although some authors [13] think that this procedure is contraindicated concomitant with a prosthesis placed, we have done it at times and do not affect the future functionality of the thumb.

#### **9. Handling with complications. Is it possible to successfully overcome a prosthesis that fails?**

It has been written in some papers that it is very difficult to get out of the failures of total prosthesis TMCJ, however, the 5% of prosthetic failures that have existed in these 17 years, of the more than 600 arthroplasties we have done have been solved without difficulty, with no more than two additional interventions to the first of the prosthesis. Similarly thinks Apard and Saint Cast [30].

Most of the complications we have had [16,18,23] were due to an error in the indication and/or in the surgical technique, the same opinion was sustained by Van Capelle et al [27], about the De la Cafiniere implants. Regarding surgical technique, it must be taken into account that there is a significant learning curve; since in our series of the first 140 prostheses [18], five of the seven major complications (four dislocations and a false passage of metacarpal stem), occurred in the first 22 prostheses, and the other two in the remaining 118.

The complications with the Arpe prosthesis have been in the short term (less than 3 months): malposition of the components, and early dislocations. In the long-term: loosening of the cup and late dislocations. There are no instances of loosening of the metacarpal stem. One quality to be required to a surgical technique is that in case of failure it could be applied other therapeutic options.

If a prosthesis fails in the short term, there are several options: a) If the failure is a malposition of the components (generally the cup), what we have done in a few cases is a surgical revision and repositioning them as soon as possible, to facilitate the procedure. b) When exists a dislocation in the short term (before three months postop) and is due to a forced movement or by an insufficient immobilization time, and the prosthetic components in correct position, it should be done a

closed reduction followed by a three weeks immobilization. If the components are malpositioned, it is necessary surgical revision and repositioning.

In the loosening of the cup, there exist three possibilities:

1. May occur that the cup is well positioned, the prosthesis continues functional and painless, which we have seen in some patients, in these, we follow an expectant conduct, with periodic reviews. 2. When the cup is loose, displaced and the patient has pain, we have to do surgical revision. At this moment, If the trapeze has a good bone stock and can put up with a new cup, our attitude is fill and compact the hole with autologous bone and then install a new cup. But if the trapeze was destroyed, it must be removed the trapeze, the cup, and the neck, and also remove the stem. Then is possible to do a trapezectomy or perform an LRTI Burton's type, which preserve better the length of the thumb. Sometimes is impossible removing the stem because has a strong integration into bone, in these cases it is better left it remaining into the bone instead of make a fracture of the metacarpal. Then, in spite of the medullar cavity is full-filled by the stem, LRTI is possible, but the tendon flap must be pass by an external subperiostic buttonhole made between metacarpal metaphysis and the insertion of the APB, being the rest of process equal.

#### **Summary**

We can conclude: 1st) The long-term survival of the spherical type arthroplasties Arpe is higher than 93%; 2nd) prostheses continue at 10 years of evolution with the same functionality as in the mid-term review (5 years); 3rd) the appropriate indication (50-65 of age, with good bone mass and size of the trapezoid) is the factor that most influences the final outcome of these arthroplasties, 4th) surgical technique must be precise and refined, which requires considerable learning curve, and 5th) even so, there is a certain tolerance, as small mal-position of the prosthetic components, seen in radiology, have no functional impact.

## References

- Gervis WH. (1949). Excision of the trapezium for osteoarthritis of the trapezio-metacarpal joint. *J Bone Joint Surg Br.* 31: 537-539.
- Froimson AL. (1970). Tendon arthroplasty of the trapeziometacarpal joint. *Clin Orthop.* 70: 191-199.
- Burton RI, Pellegrini VD. (1986). Surgical management of basal joint arthritis of the thumb: Part II. Ligament reconstruction with tendon interposition arthroplasty. *J. Hand Surg Am.* 11: 324-332.
- Pellegrini VD. (1991). Osteoarthritis of the thumb trapeziometacarpal joint: a study of the pathophysiology of articular cartilage degeneration. II. Articular wear pattern in the osteoarthritic joint. *J Hand Surg Am.* 16: 975-982.
- Zancolli EA, Zancolli ER, Cagnone JC. (2000). Rizartrosis del pulgar. Tratamiento quirúrgico en estados iniciales y tardíos. *Rev Iberamer. Cir Mano.* 27: 8-18.
- Scheker LR. (2000). Artroplastia de suspensión dinámica en la osteoartritis trapecio-metacarpiana. *Rev Iberamer Cir Mano.* 27: 19-30.
- Muller GM. (1949). Arthrodesis of the trapezio-metacarpal joint for osteoarthritis. *J Bone Joint Surg Am.* 31: 540-542.
- Swanson AB. (1968). Silicone –rubber implants for replacement of arthritic or destroyed joint in the hand. *Surg Clin North Am.* 48: 1113-27.
- Saffar P. (1993). Arthritis of the base of the thumb. En: *The Hand.* Tubiana R (Ed). Vol. 5. Philadelphia, W. B. Saunders Company. 395-417.
- Eaton R, Littler JW. (1973). Ligament reconstruction for the painful thumb carpometacarpal joint. *J Bone Joint Surg Am.* 55: 1655-61.
- De la Caffinière J Y. (1974). Prothèse totale trapézométacarpienne. *Rev Chir Orthop.* 60: 299-308.
- Chakrabarti AJ, Robinson AH, Gallagher P. (1997). De la Caffinière thumb carpometacarpal replacements: 93 cases at 6 to 16 years follow-up. *J Hand Surg [Br].* 22: 695-698.
- Cooney WP, Linscheid RL, Askew LJ. (1987). Total arthroplasty of the thumb trapeziometacarpal joint. *Clin Orthop.* 220: 35-45.
- Tomaino M M, King J, Leit M. (2007). Artrosis de la articulación de la base del pulgar. En Green DP, Pederson WC, Hotchkiss RN, Wolfe SW (Ed). *Green's Cirugía de la mano.* Madrid: Marban. 461-485.
- Brutus J P, Kinnen L. (2004). Remplacement prothétique total trapézométacarpienne au moyen de la prothèse ARPE dans le traitement de la rhizarthrose: notre expérience á court terme dans une série personnelle de 63 cas consécutifs. *Chir Main.* 23: 224-8.
- M. Martin-Ferrero. (2014). Ten-year long term results of total joint arthroplasties with ARPE implant in the treatment of trapeziometacarpal osteoarthritis. *The Journal of Hand Surgery European [JHS(E)]* (ISSN: 1753-1934). 39E: 826-32.
- Rosales RS, Delgado EB, Dies de la Lastra-Bosch I. (2002). Evaluation of the Spanish version of the DASH and carpal tunnel syndrome health-related quality-of-life instruments: cross-cultural adaptation process and reliability. *J Hand Surg Am.* 27: 334-343.
- Simón Pérez C, Rodríguez Mateos JI, Pérez Pastor C, Martín Ferrero MA. (2007). Treatment of trapezius-metacarpal arthrosis by means of total Arpe-type arthroplasty. Modification of the technique. *Rev. Iberoamericana Hand Surgery.* 35: 39-51.
- Comtet JJ. (2000). ARPE Prostheses. *Hand Arthroplasties, London, Martin-Dunitz.* 29: 249-256.
- Comtet JJ, Rumelhart C. (2001). Prothèses total trapézométacarpiennes: concepts et essai de classification. *Chir main.* 20: 48-54.
- Simonetta C. (1977). Les syndromes compressifs des nerfs périphériques du membre supérieur. *Acta Orthop Belgium.* 43: 171-176.
- Martín Ferrero MA. (2002). Integral treatment of Rizartrosis. Pp 101-113. In: *Updating Courses.* 39 SECOT National Congress. D.L. B-40.571-2002.
- Martin-Ferrero MA, Simón Pérez C, Mayo Iscar A, García Medrano B, Marcos Rodriguez JJ, et al. (2014). Long-term study (more than 10 years of evolution), complications of ARPE-type trapezo-metacarpal arthroplasties. *Rev Iberamer Cir Mano.* 42:

107-118.

24. De la Caffinière JY. (1974). Prothèse totale trapezométacarpienne. *Rev Chir Orthop.* 60: 299-308.

25. Amillo S, Samper A, Illescas JA. (2002). Long-term results of total arthroplasty of the trapeziometacarpal joint by means of the cementitious prosthesis "de la Caffinière" trapeziometacarpiana using the cemented prosthesis "de la Caffinière" 121 *Rev Med Univ Navarra.* 46: 17-20.

26. Sondergaard L, Konradsen L, Rechnagel K. (1991). Long-term follow-up of the cemented Caffiniere prosthesis for trapeziometacarpal arthroplasty. *J Hand Surg [Br].* 16: 428-430.

27. Van Cappelle HG, Elzenga P, van Horn JR. (1999). Long-term results and loosening analysis of the Caffiniere replacements of the trapeziometacarpal joint. *J Hand Surg.* 24: 476-482.

28. De la Caffinière JY. (2001). Facteurs de longévité des prothèses total trapézométacarpiennes. *Chir Main.* 20: 63-67.

29. Nicholas RM, Calderwood JW. (1992). De la Caffiniere arthroplasty for basal joint osteoarthritis. *J Bone Joint Surg Br.* 74: 309-312.

30. Apard T, Saint-Cast Y. (2007). The reprints of protheses trapezométacarpiennes ARPE® for trapezectomy. Ligamentoplastie selon la technique de Jones: une étude homogène de six cas et revue de la littérature. *Chir Main.* 26: 95-102.