

The Current Role of Minimal Invasive Surgery in Orthopaedics – A General Overview

Christian X Fang*, Kenny YH Kwan, Simon CP Yuen and Steve MH Cheung

Department of Orthopaedics and Traumatology, Li Ka Shing Faculty of Medicine, The University of Hong Kong, Hong Kong

ARTICLE INFO

Article history:

Received: 31 May 2017

Accepted: 10 July 2017

Published: 17 July 2017

Keywords:

Minimal invasive surgery;

Orthopaedics;

MISS;

MIPO

Copyright: © 2017 Fang CX et al.,

Ann Orthop Trauma Rehabil

This is an open access article distributed under the Creative Commons Attribution License, which permits unrestricted use, distribution, and reproduction in any medium, provided the original work is properly cited.

Citation this article: Fang CX, Kwan K YH, Yuen S CP, Cheung S MH. The Current Role of Minimal Invasive Surgery in Orthopaedics – A General Overview. Ann Orthop Trauma Rehabil. 2017; 1(1):115.

ABSTRACT

The goal of Minimal Invasive Surgery (MIS) is to reduce surgical trauma and shorten recovery. The scope of MIS in orthopaedics and traumatology is very wide. The current article is a brief overview of the status of MIS in fracture repair, spine surgery, joint replacement surgery, sport and arthroscopic surgery. Such goal is not always achieved in all clinical scenarios.

The use of modern intramedullary nails and sub-muscular plating has revolutionized orthopaedic trauma care in the past two decades. There is much evidence supporting routine use for lower limb fractures. In the upper limb fractures, evidence still supports open surgery to play a large role. For joint replacement surgery of the knee and hip, evidence has pointed out the lack of benefit, steep learning curve and higher risk of complications and is therefore not widespread. For spine surgery, MIS has a recognized role in spine trauma, degenerative lumbar conditions, spinal metastasis and deformity correction with some limitations to overcome. For sports surgery, arthroscopic treatment is becoming the standard of care of intraarticular conditions involving large joints, with indications expanding to smaller joints. Advancement in computer navigation, intraoperative advanced imaging and 3D printing is enabling new horizons for MIS in orthopaedics.

The benefits of MIS are realized via technological innovations and proficient surgical skills. For most conditions, MIS is performed depending on surgeon preference, and clear indications for routine use remains to be defined by high quality clinical studies.

Introduction

The role of Minimal Invasive Surgery (MIS) in orthopaedics is substantial. The goal is to decrease surgical trauma, bleeding, recovery duration and hospital length of stay and postoperative morbidities. Scars are cosmetically more appealing without compromising surgical objectives. MIS may offer expanded treatment options. We present a current overview of MIS on fracture repair, spine surgery, joint replacement, and sports surgery.

Minimal Invasive Fracture Repair

Fracture repair by MIS is widespread. The principle is to minimize further trauma to the compromised soft tissue, and minimally disrupt the fracture hematoma and periosteal blood supply.

Correspondence:

Christian X Fang,

Department of Orthopaedics and Traumatology, Li Ka Shing Faculty of Medicine, The University of Hong Kong, Queen Mary Hospital, Gleneagles Hong Kong Hospital and HKU Shenzhen Hospital, Hong Kong,
Tel: + 852 22554654;
Fax: +852 28174932;
Email: Cfang@hku.hk

The fracture is stabilized internally and patients are allowed to mobilize early without the need for external bracing or casting. In many instances, patients are encouraged to perform self-care chores and bare weight soon after surgery. Healing is promoted by callus formation. Wound complication is significantly reduced in areas with thin soft tissue envelope such as the tibia and calcaneus [1]. When needed, implant removal can follow the same minimal invasive route.

1. Closed reduction and internal fixation

The two most established MIS techniques for fracture repair in long bones are by Intra Medullary (IM) nailing and Minimal Invasive Plate Osteosynthesis (MIPO). Pioneered by Küntscher in 1939, IM nails are standard treatment for long bone shaft fractures in the femur and tibia. In the elderly, IM nails have become routine in managing fragility intertrochanteric fractures. Open fractures are manageable by early IM fixation with less worry of exposed hardware. Titanium Elastic Nails (TEN) are common treatment for paediatric long bone and adult clavicular fractures with reduced wound complications [2]. Current generation of IM nails have improved locking mechanisms that offer improved fixation in and extended indications in the periarticular regions.

MIPO is evolved from open reduction internal fixation by plating, popularized by Krettek in the 90s. MIPO is indicated for periarticular and metaphyseal fractures at the proximal humerus [3], distal femur [4] and both ends of tibia [5]. Minimal incisions are used and plates are 'slid' under the sub-muscular plane with screws placed through stab incisions. Modern low contact, anatomically shaped plates with angular stable locking screws have reduced prominence and considerably improved anchorage in osteoporotic bone. Because of superior mechanical stability in cancellous bone, MIPO is more applicable to fractures at metaphyseal and periarticular areas.

In both nailing and MIPO, fracture reduction is carried out indirectly under fluoroscopic control. The operator must ensure accurate fracture reduction and correct implant placement. Ample surgical and anatomical knowledge is mandatory in preventing neurovascular injuries [6]. Surgeons and operation room staff are unfortunately at additional risk of radiation exposure. Incorrectly performed minimal invasive surgery have risks of poor reduction, malunion and non-union. As the main aim of operative treatment remains to be fracture reduction, stabilization and early rehabilitation, open or 'mini-open' surgery is still required for displaced fractures with compromised articular congruity.

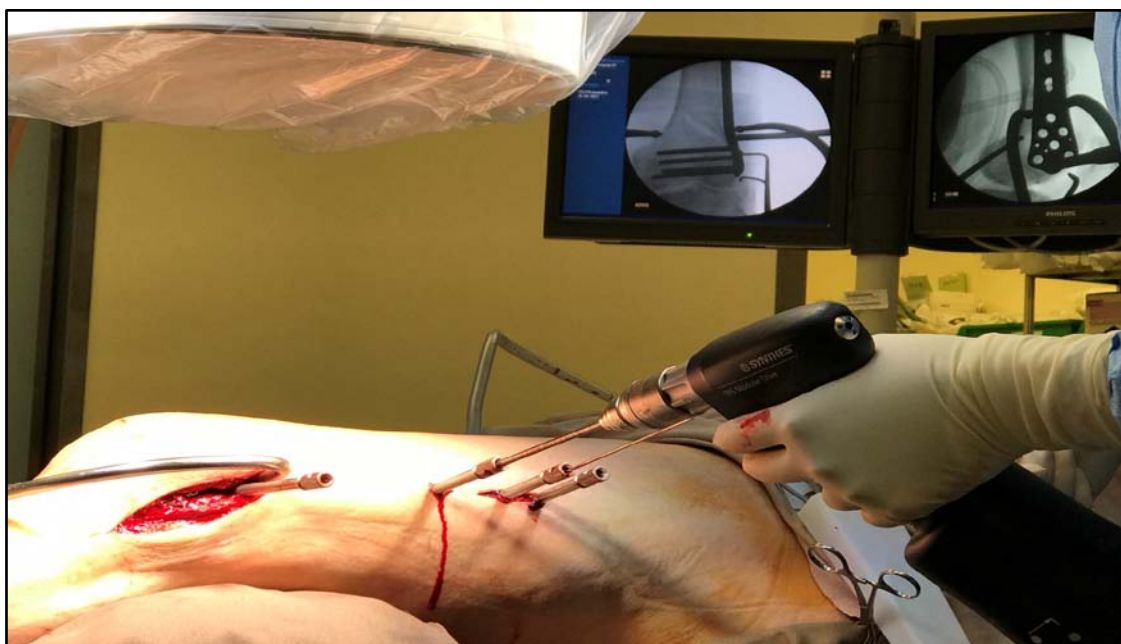


Figure 1: Minimal invasive plate osteosynthesis of a distal femur fracture. A long plate is inserted sub-muscularly using a larger lateral distal incision and stab wounds for screw placement. Fracture reduction is by a condylar reduction clamp monitored under fluoroscopy.

2. Future direction

Arthroscopic assisted fracture repair is viable for fractures that involves medium to large size joints, advocated for improved reduction, less radiation and reduced surgical trauma. High-tech percutaneous MIS techniques by 3D computer navigation or CT guided fixation is increasingly popular for treatment of pelvic ring and acetabular fractures [7]. The concept of pre-operative navigation is realized via 3D printed guides, with early evidence validating its role in management of post-traumatic deformities [8].

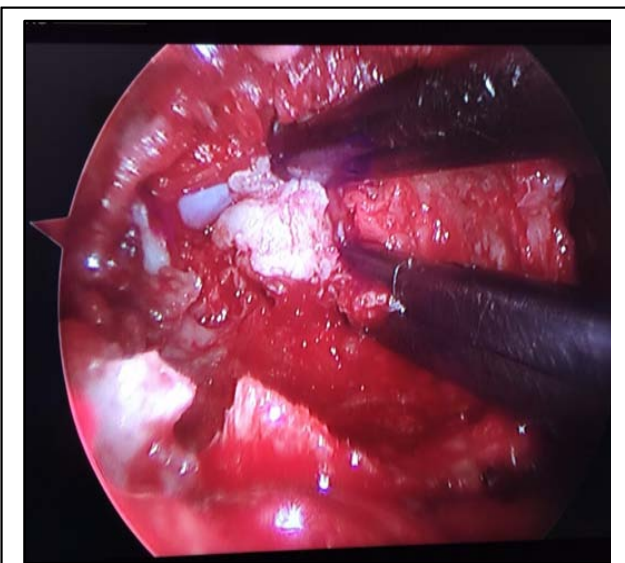


Figure 2: Microendoscopic view of lumbar discectomy for prolapsed intervertebral disc.

There is robust evidence to support the routine use of minimal invasive fracture repair. Techniques will undoubtedly evolve in a direction where surgical trauma further reduced with improved fracture reduction and stability. There will be continued debate on the best choice of approaches and implants. For example, routine use of IM nails in the humerus is disputed to have slightly higher complications than plating [9] due to shoulder joint impingement and lack of rotational control. More evidence will better define standard treatment indications (Figure 1).

Minimally Invasive Spine Surgery

Minimally Invasive Spine Surgery (MISS) is relatively novel that has emerged in the latter half of the last

century. The scope of MISS has expanded rapidly, and MISS techniques can now be applied in complex spinal pathologies and in patients with comorbidities that would make open surgeries challenging [10].

1. Spine trauma

Fractures of the thoracic and lumbar spine are indicated for surgical intervention in the presence of instability, deformity, neurological compromise, intractable pain with or without non-union. The simplest form of intervention is vertebroplasty, which utilises a percutaneous transpedicular approach for Poly Methyl Meth Acrylate (PMMA) cement injection into the vertebral body under fluoroscopic guidance. Clinical evidence for the use of vertebroplasty has changed throughout the years, with two initial Randomized Controlled Trials (RCTs) showing minimal benefit when compared with placebo [11], more recent RCTs have demonstrated clinical benefit for pain relief and hospital length of stay [12]. The ability to restore vertebral height is further augmented with kyphoplasty, whereby an inflatable balloon or stent is placed transpedicularly to improve the sagittal alignment before PMMA cement is introduced. MIS instrumentation and fluoroscopic techniques now allow more complex interventions with the use of percutaneous fixation with pedicle screws to stabilize the spinal column.

2. Degenerative lumbar conditions

Prolapsed Intervertebral Disc (PID) and spinal stenosis with or without associated instability are the commonest indication for surgical intervention in the lumbar spine. MISS techniques can be applied using tubular retractors and assisted by microscope or endoscope to decompress the spinal canal and perform discectomy. The surgical approach can be via the more traditional posterior route, or a transforaminal approach using a percutaneous endoscope. The learning curve for these procedures is variable and maybe associated with higher complication rates, particularly with low-volume practices [13]. MISS decreases surgical trauma and postoperative pain, which leads to improved recovery and decreased hospital length of stay, although there is still a paucity of high quality evidence to support this,

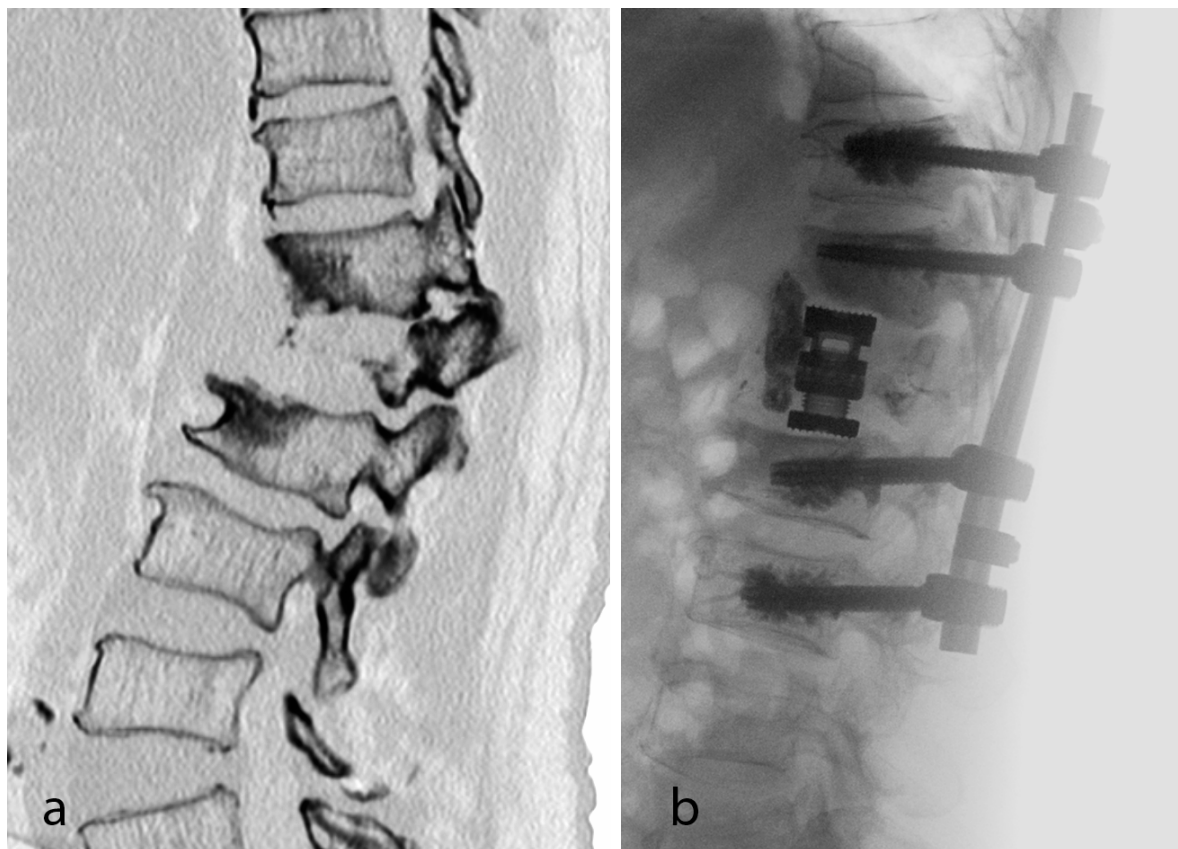


Figure 3: (a) Preoperative CT of a patient with vascular tumor of L1 with kyphotic deformity. (b) Postoperative radiograph after embolization, correction by anterior cage via MIS lateral approach and cement augmented percutaneous posterior spinal instrumentation.

and its cost-effectiveness is still undetermined [14] (Figure 2).

3. Symptomatic spinal metastases

Palliative surgery for symptomatic spinal metastases can relieve neurological compression, pain and stabilize the spine. Traditional open techniques may not be suitable for this group of patients with multiple morbidities and shorter life expectancies, but MIS techniques means some of these surgical interventions can be performed under local anaesthesia or with less surgical dissection and intraoperative blood loss. Long segment stabilization using percutaneous screw fixation and small surgical wounds for decompression at the site of spinal cord compression have led to satisfactory surgical outcomes [15].

4. Spinal deformity

Perhaps one of the most significant developments in MISS is the use of lateral access approach for anterior column reconstruction and sagittal profile realignment in Adult Spinal Deformity (ASD). Open anterior surgeries require extensive incisions and muscle dissections with

considerable postoperative complications. Lateral access approach uses a smaller wound with the assistance of retractors and intraoperative neuro monitoring for inter body fusions that lead to more powerful deformity correction in the coronal and sagittal planes. Several studies have now shown that MISS in ASD can achieve good clinical outcomes [16], and may be more suitable for the elderly who cannot undergo large reconstructive surgeries. However, there is still controversy amongst spine surgeons as to the best indications for MISS in ASD corrections (Figure 3).

5. Limitations

Careful patient selection and understanding the limitation of each MISS technique in addressing the specific pathologies are paramount in achieving a good clinical outcome. There is evidence that decompression of the central canal and lateral recess is not always achievable with lateral interbody fusion [17], and not all deformities can be corrected adequately using MISS [18]. Robust evidence is also lacking whether MISS techniques are translated to improved clinical outcomes

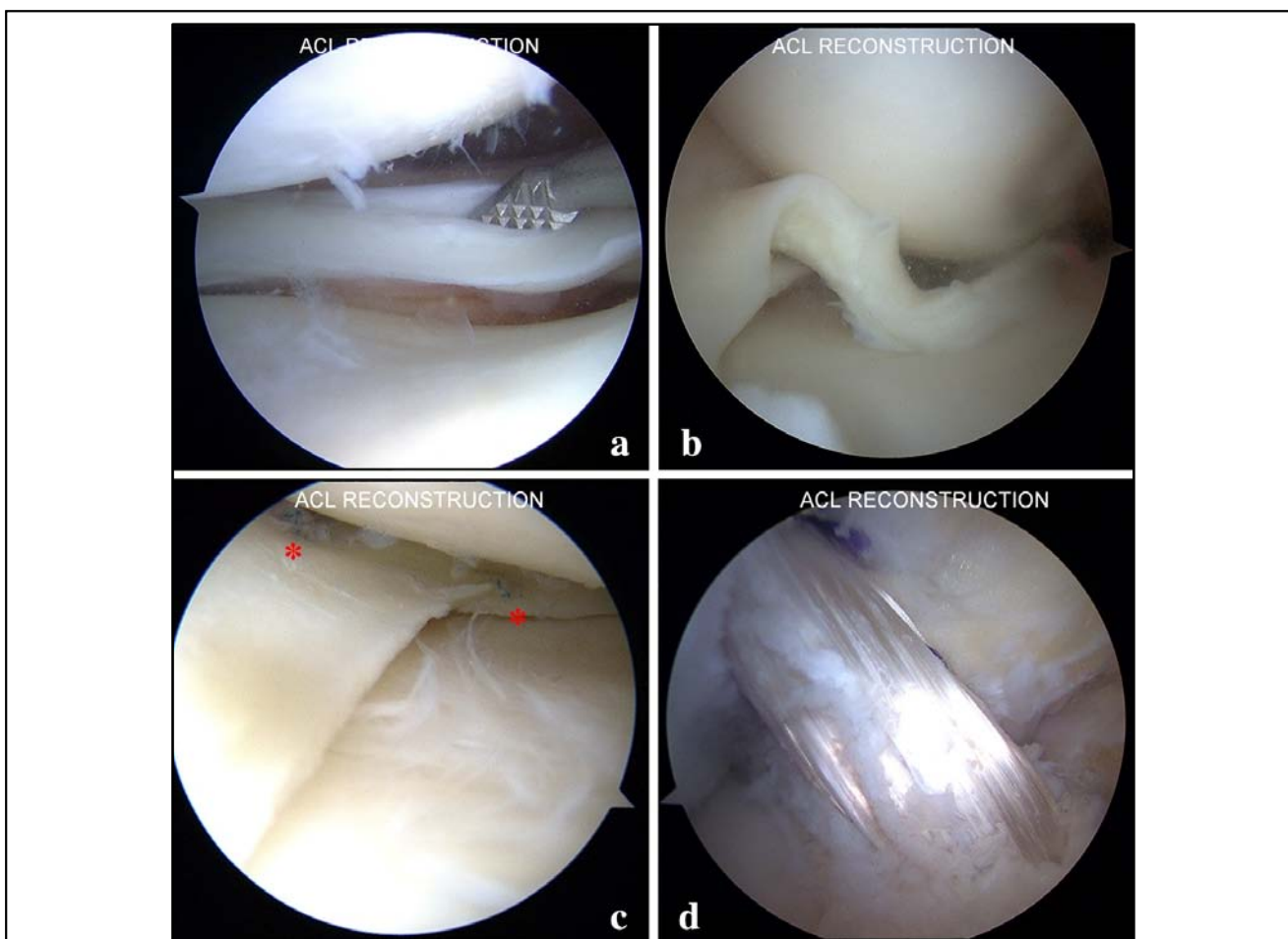


Figure 4: Application of knee arthroscopy. a: Longitudinal meniscal tear. b: Bucket-handle meniscal tear. c: Meniscal repair with all-inside suture technique (asterisk). d: ACL reconstruction with satisfactory tension of the graft.

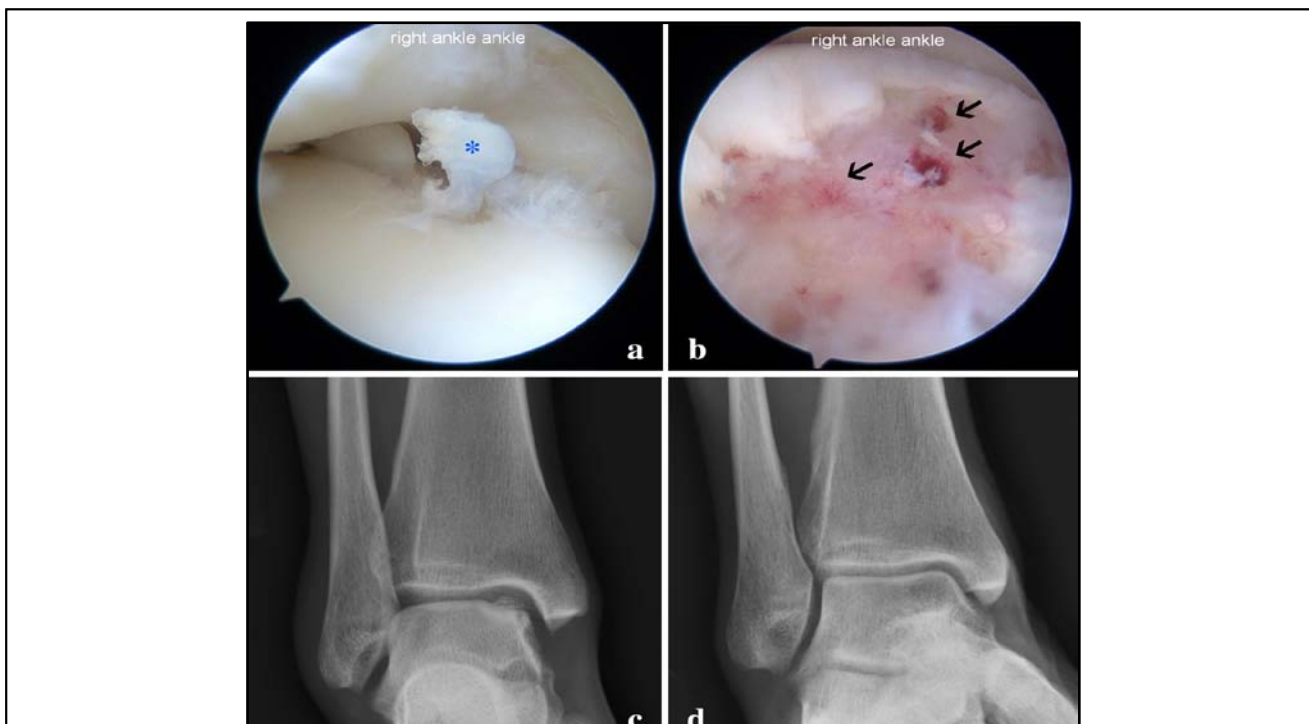

Figure 5: Application of ankle arthroscopy. a: Osteochondral lesion of talus with full-thickness cartilage flap (asterisk). b: Debridement and microfracture stimulates subchondral bleeding and development of a fibrin clot (arrows). c: Pre-operative XR showed significant talar dome chondral defect with subcondral sclerosis. d: Satisfactory chondral remodelling occurred in 4 months post-operatively.

for lumbar disc herniation compared with conventional microdiscectomy [19]. Moreover, the costs for MISS are higher in most instances, and its cost-effectiveness remains unproven [14].

In summary, there are new and confirmatory evidence that MISS advancements can be applied in different spinal conditions safely and effectively. Responsible applications with appropriate choice of MISS techniques in carefully selected patients are key to success. Continual evolution and refinement of our knowledge, techniques in MISS and more high-quality studies to support its use will lead to more widespread use and improved patient care.

Minimally Invasive Joint Replacement Surgery

MIS joint replacement surgery is not a single type of surgery nor a certain surgical approach. It's a concept which aims to achieve a smaller incision and, less soft tissue trauma [20]. Through MIS approach joint surgeons hopefully can improve surgical outcome and patient's satisfaction by reduction of blood loss, postoperative pain, improvement of cosmesis, accelerated discharge and enhanced recovery.

1. Knee arthroplasty

MIS arthroplasty was introduced in early 1990s by Repicci for the Unicompartamental Knee Arthroplasty (UKA) [21]. In early 2000s the same concept spread to Total Knee Arthroplasty (TKA). Four major approaches to MIS TKR have been developed: Quadriceps sparing, mini-midvastus, mini-subvastus, and the mini-para-patellar [22, 23]. Quadriceps sparing approach was coined by Alfred Tria in 2000 [24]. The skin incision was still 10 cm in length and the arthrotomy extended from the superior pole of the patella to 2 cm below the tibial joint line over the medial side, without cutting through quadriceps tendon and muscle. His visit to Hong Kong in 2006 with his surgical demonstration popularized this in the territory for a few years.

2. Hip arthroplasty

MIS THA (Total Hip Arthroplasty) was introduced by pioneers including Richard Berger and Dana Mears in mid 1990s. The two common approaches to MIS are the single-incision and two-incision approach. The former

involves one single mini incision (usually defined as < 10cm) through either posterior, anterolateral [25] or posterolateral approach. The latter comprised of one anterior incision for preparing the acetabulum and cup insertion, and a second posterior incision for femur preparation and stem insertion.

Due to the limited visual field, intraoperative verification of stem and cup position commonly require fluoroscopic assistance [20]. Similar to MIS TKA, specially designed instruments including retractors, handle, reamers and bone-shaping tool are needed.

3. Current evidence and limitations

A number of studies and meta-analysis has been published comparing the short term result between MIS and conventional joint replacement. While the results are heterogeneous, it is generally agreed that current evidence does not demonstrate clear superiority of MIS against conventional joint replacement [26-28]. Moreover, there are modest evidence demonstrating inferior outcome of MIS joint replacement in terms of radiological component alignment [29, 30]. Given the fact that there is no long term data available, current evidence make the hypothetical benefits of MIS questionable.

Most MIS approaches require special instruments in a restricted operative field [31]. To guarantee correct implant alignment, adjunctive technologies like computer navigation [32,33], Patient Specific Instrumentation (PSI) [34], robotic assisted surgery is often required. All factors lead to prolonged operative time and extra learning curve to acquire the essential skills [35]. Combined factors above, the initial enthusiasm for MIS quieted and pendulum was then switched back to conventional approach. Currently most arthroplasty surgeons apply the MIS approach to specific operations only (e.g. UKA). While the concept of MIS is theoretically sound, scientific support is lacking. Joint replacement surgeons who plan to use MIS in usual clinical practice should critically evaluate the procedure and pay extra attention in patient selection.

Arthroscopic and Endoscopic Surgery

Innovation in arthroscopic surgery in the last century has fundamentally changed the standard of care for many intraarticular and periarticular pathologies, especially in the field of sports medicine. Sometimes seen as synonymous with minimal invasive orthopaedic surgery, the endoscope is in reality only a tool. Its utility in complex procedures is driven by advancements in technology and skills. Arthroscopes as small as 1.3mm gives satisfactory vision in small joints. Arthroscopic implants, suture anchors, electro-surgery devices have seen rapid proliferation along with improved techniques and training.

1. The knee

Watanabe developed the first truly working arthroscope and performed the first recorded arthroscopic partial meniscectomy in 1962. Since then, knee arthroscopy is very common. The American Academy of Orthopaedic Surgeons estimates 636,000 such procedures each year in the United States, with more than half performed for meniscal pathologies. The benefits of knee arthroscopy are well documented. Open meniscectomy and open anterior cruciate ligament reconstruction is now nearly obsolete.

Arthroscopic knee surgery can be diagnostic or interventional, indicated for meniscal, ligamentous, patellofemoral, neoplastic, loose body, arthritic, cartilage conditions, and fractures. Meniscal procedures can be meniscectomy or repair. Anterior and posterior cruciate ligament reconstruction is a standard procedure supported by evidence with clearly defined indications. Patellofemoral procedure is mainly for patellar instability. Chondral procedure including debridement, micro-fracture and osteochondral transplantation have weaker evidence of support for degenerative conditions [36-39] (Figure 4).

2. The shoulder

Arthroscopic shoulder surgery is popular. Advocates claim better visualization of the glenohumeral joint and the sub-acromial space, and more thorough releases of deeper tendon and capsular contractures. For rotator cuff repair, open shoulder surgery and arthroscopy

demonstrated similar results [40]. Provided adequate skills, arthroscopic management of recurrent shoulder instability, impingement syndrome, bicep tenodinitis and acromioclavicular joint pathology is considered a standard alternative to open surgery [41]. Open or mini-open surgery is reserved for complex or revision situations.

3. The ankle

Anterior ankle, posterior ankle and subtalar joints are all accessible by arthroscopy. It can be used for both diagnostic and therapeutic purpose, be it repair, reconstruction or fusion. Arthroscopic ankle fusion is a standard treatment forend-stage ankle arthritis. Under arthroscopic view, the articular cartilage and subchondral bone is removed with by curettage and burr. Two or three percutaneous cannulated screws are placed across the joint under fluoroscopic guidance to achieve gap compression and fusion. Evidence have demonstrated shorter recovery and improved union rates [42].

With the success of arthroscopic ankle fusion, arthroscopic fusion is applied to subtalar and midfootjoints. Management of osteochondral lesion of talus, ankle synovitis, post-traumatic impingement, excision of anterior osteophyte or ostrigonum, and repair or reconstruction of lateral ankle instability secondary to ankle sprain can be performed arthroscopically [43,44].

Apart from arthroscopy, endoscopic and tendoscopic procedures have become more widespread. Endoscopic calcaneoplasty for Haglund's disease and endoscopic plantar fasciotomy for recalcitrant plantar fasciitis have been reported to be safer then open procedure [45]. Tendoscope in the foot and ankle region is mainly for posterior tibial tendon dysfunction, being both diagnostic and therapeutic [46]. Minimal invasive Achilles tendon repair have reduced wound complications and similar functional outcome compared to open repair (Figure 5).

4. The wrist

Wrist arthroscopy was first described by Chen in 1979 [47], with initial application limited to partial evaluation of the joint surface. With better distraction techniques and precise portal placement, treatment indications have

expanded exponentially. While open arthrotomy is suboptimal in visualizing subtle pathologies, wrist arthroscopy allows magnified visual examination of the articular surfaces and wrist ligaments. For diagnosis, wrist arthroscopy is an accurate complement to ordinary examination. It is useful in patients with interosseous ligaments tears, carpal instability, Kienbock's disease, and scapholunate or lunotriquetral dissociations [48].

Wrist arthroscopic intervention is indicated for loose body removal, synovectomy, debridement, intra-articular adhesion release, tears of the triangular fibrocartilage complex, ganglion excision, distal radius and scaphoid fracture fixation, and radialstyloidectomy [49,50]. Recently, more advanced arthroscopic procedures, such as proximal row carpectomy, limited carpal resection or fusion, and scaphoid non-union have been reported [51].

5. The elbow

Elbow arthroscopy was originally used for diagnostic procedure or removal of loose bodies [52]. With advancement in technique, the indications for arthroscopic treatment have extended to tennis elbow, posttraumatic contracture capsular release, synovectomy, osteochondral lesions and intra-articular (capitellar and coronoid) fracture fixation [53,54].

6. The hip

Hip arthroscopy was first described in 1931 [55]. However its role was limited until 1980s when several authors started to advocate hip arthroscopy as a result of advancements in portal location, traction technique, surgical equipment and experience [56]. Hip arthroscopy is used in diagnosis and treatment of labral tears, removal of loose bodies, management of femoroacetabular impingement, degenerative arthritis, cartilage damage, synovial lesions and avascular necrosis of the femoral head [57].

7. Small joints

With precise and fine arthroscope and instruments, the clinical application of small joint arthroscopies (metatarsophalangeal joint, Lisfranc joint, Chopart joint, and interphalangeal joint) in the foot has seen significant advancements. Arthroscopic techniques for large joint pathologies are being exploited correspondingly in

small joints. Early studies have found comparable results for arthroscopic soft tissue procedures and arthrodesis of the small joints when compared with open approach [58].

In conclusion, arthroscopy is just another tool in the surgeon's armamentarium. The benefits are appealing for a broad range of pathological conditions. Treatment must be decided on an individual case-by-case basis. Appropriate use of such tools should lead to improved patient outcome.

Conclusion

The benefits of MIS are realized via technological innovations, skills and correct surgical indications. We have provided a brief overview of the numerous surgical options for the musculoskeletal system. Because it is less likely that any single orthopaedist can master all of them, subspecialized training and a sound patient referral system will be important future foundations. Evidence based medicine will continue to help us define the most appropriate treatment indications.

References

1. Kline AJ, Anderson RB, Davis WH, Jones CP, Cohen BE. (2013). Minimally invasive technique versus an extensile lateral approach for intra-articular calcaneal fractures. *Foot Ankle Int.* 34: 773-780.
2. Saha P, Datta P, Ayan S, Garg AK, Bandyopadhyay U, et al. (2014). Plate versus titanium elastic nail in treatment of displaced midshaft clavicle fractures: A comparative study. *Indian Journal of Orthopaedics.* 48: 587-593.
3. Sohn HS, Jeon YS, Lee J, Shin SJ. (2017). Clinical comparison between open plating and minimally invasive plate osteosynthesis for displaced proximal humeral fractures: A prospective randomized controlled trial. *Injury.* 48: 1175-1182.
4. Krettek C, Schandelmaier P, Miclau T, Tschernke H. (1997). Minimally Invasive Percutaneous Plate Osteosynthesis (MIPPO) using the DCS in proximal and distal femoral fractures. *Injury.* 28 Suppl. 1: A20-30.
5. Cole PA, Zlowodzki M, Kregor PJ. (2004). Treatment of proximal tibia fractures using the less

invasive stabilization system: surgical experience and early clinical results in 77 fractures. *J Orthop Trauma*. 18: 528-535.

6. Apivatthakakul T, Arpornchayanon O, Bavornratanavech S. (2005). Minimally Invasive Plate Osteosynthesis (MIPO) of the humeral shaft fracture. *Injury*. 36: 530-538.

7. Wong JM, Bewsher S, Yew J, Bucknill A, de Steiger R. (2015). Fluoroscopically assisted computer navigation enables accurate percutaneous screw placement for pelvic and acetabular fracture fixation. *Injury*. 46: 1064-1068.

8. Stockmans F, Dezillie M, Vanhaecke J. (2013). Accuracy of 3D Virtual Planning of Corrective Osteotomies of the Distal Radius. *Journal of Wrist Surgery*. 2: 306-314.

9. Zhao JG, Wang J, Wang C, Kan SL. (2015). Intramedullary Nail Versus Plate Fixation for Humeral Shaft Fractures: A Systematic Review of Overlapping Meta-analyses. *Medicine*. 94: e599.

10. Rodgers WB, Cox CS, Gerber EJ. (2010). Early complications of extreme lateral interbody fusion in the obese. *J Spinal Disord Tech*. 23: 393-397.

11. Buchbinder R, Osborne RH, Ebeling PR, Wark JD, Mitchell P, et al. (2009). A randomized trial of vertebroplasty for painful osteoporotic vertebral fractures. *N Engl J Med*. 361: 557-568.

12. Clark W BP, Gonski P, Diamond TH, Smerdely P, McNeil HP, et al. (2016). Safety and efficacy of Vertebroplasty For Acute Painful Osteoporotic Fractures (VAPOUR): a multicentre, randomised, double-blind, placebo-controlled trial. *Lancet*. 388: 1408-1416.

13. Sclafani JA, Kim CW. (2014). Complications associated with the initial learning curve of minimally invasive spine surgery: a systematic review. *Clin Orthop Relat Res*. 472: 1711-1717.

14. Lubelski D, Mihalovich KE, Skelly AC, Fehlings MG, Harrop JS, et al. (2014). Is minimal access spine surgery more cost-effective than conventional spine surgery? *Spine*. 39: S65-74.

15. Hansen-Algenstaedt N, Knight R, Beyerlein J, Gessler R, Wiesner L, et al. (2013). Minimal-invasive stabilization and circumferential spinal cord

decompression in Metastatic Epidural Spinal Cord Compression (MESCC). *Eur Spine J*. 22: 2142-2144.

16. Park P, Okonkwo DO, Nguyen S, Mundis GM, Deviren V, et al. (2016). Can a Minimal Clinically Important Difference Be Achieved in Elderly Patients with Adult Spinal Deformity Who Undergo Minimally Invasive Spinal Surgery? *World Neurosurg*. 86: 168-172.

17. Lang G, Perrech M, Navarro-Ramirez R, Hussain I, Pennicooke B, et al. (2017). Potential and limitations of neural decompression in extreme lateral interbody fusion - a systematic review. *World Neurosurg*. 101: 99-113.

18. Wang MY, Mummaneni PV, Fu KM, Anand N, Okonkwo DO, et al. (2014). Less invasive surgery for treating adult spinal deformities: ceiling effects for deformity correction with 3 different techniques. *Neurosurg Focus*. 36: E12.

19. Kamper SJ, Ostelo RW, Rubinstein SM, Nellensteijn JM, Peul WC, et al. (2014). Minimally invasive surgery for lumbar disc herniation: a systematic review and meta-analysis. *Eur Spine J*. 23: 1021-1043.

20. Berry DJ, Berger RA, Callaghan JJ, Dorr LD, Duwelius PJ, Hartzband MA, et al. (2003). Minimally invasive total hip arthroplasty. Development, early results, and a critical analysis. Presented at the Annual Meeting of the American Orthopaedic Association, Charleston, South Carolina, USA, June 14, 2003. *The Journal of bone and joint surgery American volume*. 85-A: 2235-2246.

21. Repicci JA, Eberle RW. (1999). Minimally invasive surgical technique for unicondylar knee arthroplasty. *Journal of the Southern Orthopaedic Association*. 8: 20-27.

22. Tria AJ, Scuderi GR. (2015). Minimally invasive knee arthroplasty: An overview. *World journal of orthopedics*. 6: 804-811.

23. Scuderi GR, Tenholder M, Capeci C. (2004). Surgical approaches in mini-incision total knee arthroplasty. *Clinical orthopaedics and related research*. 428: 61-67.

24. Tria AJ, Jr., Coon TM. (2003). Minimal incision total knee arthroplasty: early experience. *Clinical orthopaedics and related research*. 416: 185-190.
25. Berger RA. (2004). Mini-incision total hip replacement using an anterolateral approach: technique and results. *The Orthopedic clinics of North America*. 35: 143-151.
26. Imamura M, Munro NA, Zhu S, Glazener C, Fraser C, et al. (2012). Single mini-incision total hip replacement for the management of arthritic disease of the hip: a systematic review and meta-analysis of randomized controlled trials. *The Journal of bone and joint surgery American volume*. 94: 1897-1905.
27. Unwin O, Hassaballa M, Murray J, Harries W, Porteous A. (2017). Minimally Invasive Surgery (MIS) for total knee replacement; medium term results with minimum five year follow-up. *The Knee*. 24: 454-459.
28. Ranawat CS, Ranawat AS. (2003). Minimally invasive total joint arthroplasty: where are we going? *The Journal of bone and joint surgery American volume*. 85: 2070-2071.
29. Dalury DF, Dennis DA. (2005). Mini-incision total knee arthroplasty can increase risk of component malalignment. *Clinical orthopaedics and related research*. 440: 77-81.
30. Chen AF, Alan RK, Redziniak DE, Tria AJ. (2006). Quadriceps sparing total knee replacement. The initial experience with results at two to four years. *The Journal of bone and joint surgery British volume*. 88: 1448-1453.
31. Coon TM. (2006). Specialized instruments and modular implants for minimally invasive total knee arthroplasty. *American journal of orthopedics (Belle Mead, NJ)*. 35: 12-17.
32. Chandrasekaran S, Molnar RB. (2008). Minimally invasive imageless computer-navigated knee surgery: initial results. *The Journal of arthroplasty*. 23: 441-445.
33. Luring C, Beckmann J, Haibock P, Perlick L, Grifka J, et al. (2008). Minimal invasive and computer assisted total knee replacement compared with the conventional technique: a prospective, randomised trial. *Knee surgery, sports traumatology, arthroscopy : official journal of the ESSKA*. 16: 928-934.
34. Yan CH, Chiu KY, Ng FY, Chan PK, Fang CX. (2015). Comparison between patient-specific instruments and conventional instruments and computer navigation in total knee arthroplasty: a randomized controlled trial. *Knee surgery, sports traumatology, arthroscopy : official journal of the ESSKA*. 23: 3637-3645.
35. Aglietti P, Baldini A, Giron F, Sensi L. (2006). Minimally invasive total knee arthroplasty: is it for everybody? *HSS journal : the musculoskeletal journal of Hospital for Special Surgery*. 2: 22-26.
36. Dale KM, Bailey JR, Moorman CT 3rd. (2017). Surgical Management and Treatment of the Anterior Cruciate Ligament/Medial Collateral Ligament Injured Knee. *Clinics in sports medicine*. 36: 87-103.
37. Miller MD, Harner CD. (1995). The anatomic and surgical considerations for posterior cruciate ligament reconstruction. *Instructional course lectures*. 44: 431-440.
38. Mutsaerts EL, van Eck CF, van de Graaf VA, Doornberg JN, van den Bekerom MP. (2016). Surgical interventions for meniscal tears: a closer look at the evidence. *Archives of orthopaedic and trauma surgery*. 136: 361-370.
39. Devitt BM, Bell SW, Webster KE, Feller JA, Whitehead TS. (2017). Surgical treatments of cartilage defects of the knee: Systematic review of randomised controlled trials. *The Knee*. 24: 508-517.
40. Colvin AC, Egorova N, Harrison AK, Moskowitz A, Flatow EL. (2012). National trends in rotator cuff repair. *The Journal of bone and joint surgery American volume*. 94: 227-233.
41. Caprise PA, Sekiya JK. (2006). Open and arthroscopic treatment of multidirectional instability of the shoulder. *Arthroscopy : the journal of arthroscopic & related surgery : official publication of the Arthroscopy Association of North America and the International Arthroscopy Association*. 22: 1126-1131.
42. Elmlund AO, Winson IG. (2015). Arthroscopic ankle arthrodesis. *Foot and ankle clinics*. 20: 71-80.
43. Lui TH. (2007). Arthroscopy and endoscopy of the foot and ankle: indications for new techniques.

Arthroscopy : the journal of arthroscopic & related surgery : official publication of the Arthroscopy Association of North America and the International Arthroscopy Association. 23: 889-902.

44. Yuen CP, Lui TH. (2016). Arthroscopic Triple Arthrodesis. In: Scuderi GR, Tria AJ, editors. Minimally Invasive Surgery in Orthopedics. Cham: Springer International Publishing. 1-8.

45. Chou AC, Ng SY, Koo KO. (2016). Endoscopic Plantar Fasciotomy Improves Early Postoperative Results: A Retrospective Comparison of Outcomes after Endoscopic Versus Open Plantar Fasciotomy. The Journal of foot and ankle surgery : official publication of the American College of Foot and Ankle Surgeons. 55: 9-15.

46. Monteagudo M, Maceira E. (2015). Posterior tibial tendoscopy. Foot and ankle clinics. 20: 1-13.

47. Chen YC. (1979). Arthroscopy of the wrist and finger joints. The Orthopedic clinics of North America. 10: 723-733.

48. Gupta R, Bozentka DJ, Osterman AL. (2001). Wrist arthroscopy: principles and clinical applications. The Journal of the American Academy of Orthopaedic Surgeons. 9: 200-9.

49. Estrella EP, Hung LK, Ho PC, Tse WL. (2007). Arthroscopic repair of triangular fibrocartilage complex tears. Arthroscopy: the journal of arthroscopic & related surgery : official publication of the Arthroscopy Association of North America and the International Arthroscopy Association. 23: 729-737.

50. Ho PC, Griffiths J, Lo WN, Yen CH, Hung LK. (2001). Current treatment of ganglion of the wrist. Hand surgery : an international journal devoted to hand and upper limb surgery and related research : journal of the Asia-Pacific Federation of Societies for Surgery of the Hand. 6: 49-58.

51. Jegal M, Kim JS, Kim JP. (2015). Arthroscopic Management of Scaphoid Nonunions. Hand surgery : an international journal devoted to hand and upper limb surgery and related research : journal of the Asia-Pacific Federation of Societies for Surgery of the Hand. 20: 215-221.

52. McGinty JB. (1982). Arthroscopic removal of loose bodies. The Orthopedic clinics of North America. 13: 313-328.

53. Steinmann SP, King GJ, Savoie FH. (2005). Arthroscopic treatment of the arthritic elbow. The Journal of bone and joint surgery American volume. 87: 2114-2121.

54. Pierce TP, Issa K, Gilbert BT, Hanley B, Festa A, et al. (2017). A Systematic Review of Tennis Elbow Surgery: Open Versus Arthroscopic Versus Percutaneous Release of the Common Extensor Origin. Arthroscopy : the journal of arthroscopic & related surgery : official publication of the Arthroscopy Association of North America and the International Arthroscopy Association. 33: 1260-1268.

55. Burman MS. (2001). Arthroscopy or the direct visualization of joints: an experimental cadaver study. 1931. Clinical orthopaedics and related research. 390: 5-9.

56. Glick JM. (2001). Hip arthroscopy. The lateral approach. Clinics in sports medicine. 20: 733-747.

57. Fairley J, Wang Y, Teichtahl AJ, Seneviwickrama M, Wluka AE, et al. (2016). Management options for femoroacetabular impingement: a systematic review of symptom and structural outcomes. Osteoarthritis and cartilage. 24: 1682-1696.

58. Lui TH, Yuen CP. (2015). Small joint arthroscopy in foot and ankle. Foot and ankle clinics. 20: 123-138.