

A Case Series of LIPUS Stimulation in Unstable Forearm Fractures in Children to Facilitate Bone Union

Soichiro Itoh^{1*}, Tsuyoshi Ota² and Kimihiro Yamashita^{1*}

¹Institute of Biomaterials and Bioengineering, Tokyo Medical and Dental University, Japan

²Department of Orthopaedic Surgery, Saiseikai Kawaguchi General Hospital, Japan

ARTICLE INFO

Article history:

Received: 12 June 2017

Accepted: 07 March 2018

Published: 07 March 2018

Keywords:

Forearm fracture;

Diaphysis;

Children;

Intramedullary nailing;

Low-intensity pulsed ultrasound

Copyright: © 2018 Itoh S, Yamashita K et al.,

Ann Orthop Trauma Rehabil

This is an open access article distributed under the Creative Commons Attribution License, which permits unrestricted use, distribution, and reproduction in any medium, provided the original work is properly cited.

Citation this article: Itoh S, Ota T, Yamashita K. A Case Series of LIPUS Stimulation in Unstable Forearm Fractures in Children to Facilitate Bone Union. Ann Orthop Trauma Rehabil. 2018; 2(1):118.

Correspondence:

Dr. Soichiro Itoh,
Department of Inorganic
Materials, Institute of Biomaterials
and Bioengineering, Tokyo
Medical and Dental University, 2-
3-10 Kanda-Surugadai, Chiyoda,
Tokyo 101-0062, Japan,
Tel: +81-3-5280-8016;
Fax: +81-3-5280-8125;
Email: itoso.gene@gmail.com

Dr. Kimihiro Yamashita,
Department of Inorganic
Materials, Institute of Biomaterials
and Bioengineering, Tokyo
Medical and Dental University, 2-
3-10 Kanda-Surugadai, Chiyoda,
Tokyo 101-0062, Japan,
Tel: +81-3-5280-8016;
Fax: +81-3-5280-8125;
Email: yama-k.bcr@tmd.ac.jp

ABSTRACT

This is an open labeled and retrospective cohort study which compared the efficacy of Low-intensity pulsed ultrasound (LIPUS) stimulation to facilitate unstable forearm fracture healing in children. Twenty five children with both radius and ulna diaphysis fractures were treated with intramedullary nailing (mean age 9.2 ± 2.6 years) using K-wires. LIPUS stimulation was applied to 15 patients and not applied to 10 patients after surgery. The time spans needed for callus appearance and bone union in the patients with LIPUS stimulation were significantly shorter than that in the patients without LIPUS stimulation. Furthermore, the period of pinning and cast immobilization tended to be shorter in the LIPUS-treated group compared with non-LIPUS-treated group. Useful functional recovery was obtained in wrist extension and flexion, as well as forearm pronation and supination in each fracture group. Results of this study support the hypothesis that intramedullary nailing and cast immobilization combined with LIPUS stimulation may be effective to facilitate fracture healing including both radius and ulna diaphysis in children.

Introduction

Open reduction and fixation using intramedullary nail is often indicated for treating unstable fractures in children, especially in cases of a diaphyseal forearm fracture [1]. Intramedullary nail fixation allows for micromotion at the fracture site caused by the elasticity of a nail, which is beneficial for rapid fracture healing [2]. Nevertheless, the rate of re-displacement is reported to be 5% without cast immobilization [3] because intramedullary nailing is less biomechanically stable with forearm pronation and supination [4]. Moreover, the mid-diaphysis of the ulna is identified as a “watershed area” in the intraosseous blood supply, where periosteal circulation is supplied from the anterior and posterior interosseous arteries [5,6]. Therefore, some sort of ancillary technology to facilitate fracture healing is desirable to prevent pseudarthrosis and delayed union caused by circulatory disturbance in the region. Prospective clinical trials have shown that low-intensity pulsed ultrasound (LIPUS) systems are clinically effective in the healing of delayed union, nonunion and fresh fracture [7]. However, there are no reports of the use of LIPUS to treat fresh forearm fractures in children. In this study, LIPUS

was used after intramedullary nailing in children to facilitate forearm fracture healing including both radius and ulna diaphysis, and the efficacy of LIPUS stimulation on such unstable fracture treatment were evaluated.

Patients and Methods

Twenty five children with both radius and ulna diaphysis fractures were treated with intramedullary nailing (22 males and 3 females, 4-15 years, mean age 9.2 ± 2.6 years) using stainless steel implants (K-wires). Any open fractures were not included in these cases. With the patient under general anesthesia, the radius and ulna diaphysis fracture were pinned with a single K-wire from the radial styloid and ulnar head to the mid-shaft. The diameter of the K-wires was selected to match the medullary canal. When the nail reached the fracture site, manipulation under traction was performed under image intensifier control, and then the nail was inserted into the proximal fragment. In all cases closed reduction was applied successfully without an open reduction. The end of the K-wire was bent and exposed on the skin. An above-the-elbow cast was applied for 4-5 weeks after operation and the K-wires were removed 5-6 weeks postoperatively.

Between August 2011 and December 2012, LIPUS stimulation was not applied to patients after surgery. Subsequently, between January 2013 and March 2015, patients were treated post-operatively with a LIPUS system (SAFHS 4000J, Teijin, Tokyo, Japan). Treatment with the LIPUS device was under the conditions of use once per day for 20 minutes for each fracture until bone union using the following parameter configuration: average intensity (I) = 30 mW/cm², ultrasound frequency (F) = 1.5 MHz, signal impulse duration = 200 microseconds, repetition rate = 1 kHz, effective radiated area = 3.88 cm² and temporal average power = 117 mW. LIPUS stimulation was applied alternately at a small window of the cast opened over each fracture site of radius and ulna.

Anterior, posterior, and lateral radiographs were taken immediately after operation, every week postoperatively and every 2 weeks after removal of wires until bone union was verified. The fracture healing

process was assessed radio graphically for the presence of a radiolucent fracture line with or without marginal sclerosis, sharp or blurry fracture margins, first appearance of callus and its bridging of involved cortices. By evaluating a loss of fracture margins or development of a bone-to-bone callus bridge, bone union was defined when bridging of more than 3/4 of the involved cortices was completed, in the anterior, posterior, medial and lateral regions [8]. The time of callus appearance was defined as the first appearance of callus in the fracture site of either radius or ulna, and bone union as both radius and ulna fractures were united. Functional recovery, including wrist extension and flexion as well as forearm pronation and supination, was measured until its improvement plateaued.

The age of the patient, waiting period until surgery, duration of cast immobilization, time needed for callus appearance and bone union, timing of pin removal, observation period after surgery and ROM in the group with and without LIPUS stimulation was compared using the Mann-Whitney U-test. The number of patients classified according to gender and injured site, and the number of cases whose reduced position was lost and re-displaced after pin removal (malunion) in the groups were compared using the chi-square test. The differences were considered statistically significant when $p < 0.05$.

No patient had any medical history of bone diseases that could have influenced the treatment results. Informed written consent was obtained from all patients who enrolled in this study. All procedures in this study were in accordance with the ethical standards of the committee responsible for approving human experimentation at the authors' institution and with the Helsinki Declaration of 1975, as revised in 2008.

Results

There were no significant differences between the baseline data in each group (Table 1). There were not any patients lost to follow up in each group. Complete bone union was obtained in all patients and no major complications, including pseudarthrosis, delayed union, infection and skin necrosis, as well as peripheral nerve,

Table 1: The baseline data including age, number of patients classified according to gender, injured site and waiting period of the groups.

	age	gender		injured site		waiting period
	(years old)	male	female	Rt	Lt	(days)
LIPUS (-)	8.2 \pm 2.5	9	1	6	4	4.4 \pm 4.7
LIPUS (+)	10.2 \pm 2.6	13	2	9	6	4.9 \pm 4.9

LIPUS (-): both radius and ulna diaphysis fracture group without LIPUS treatment

LIPUS (+): both radius and ulna diaphysis fracture group treated with LIPUS stimulation

Rt: right, Lt: left

average \pm SD

Table 2: The timing of pin removal, duration of external fixation including cast and splint immobilization, time needed for callus appearance and bone union, number of malunion and observation period after surgery.

	callus appearance (days)	pin removal (days)	External fixation (days)	bone union (days)	malunion	observation period (days)
LIPUS (-)	32.5 \pm 10.5	41.6 \pm 8.8	46.9 \pm 9.6	74.1 \pm 11.2	3	232.7 \pm 130.4
LIPUS (+)	19.0 \pm 4.8	38.9 \pm 4.7	41.6 \pm 4.0	44.1 \pm 4.8	0	162.4 \pm 76.9

LIPUS (-): both radius and ulna diaphysis fracture group without LIPUS treatment

LIPUS (+): both radius and ulna diaphysis fracture group treated with LIPUS stimulation

average \pm SD

** $p < 0.01$

Table 3: ROM, including wrist Ext and Flex as well as forearm Pro and Sup, when ROM improvement plateaued.

	Flex	Ext	Pro	Sup
LIPUS (-)	90.0 \pm 0.0	89.0 \pm 3.0	90.0 \pm 0.0	89.0 \pm 3.0
LIPUS (+)	86.0 \pm 7.8	89.3 \pm 2.5	89.7 \pm 1.2	90.0 \pm 0.0

LIPUS (-): both radius and ulna diaphysis fracture group without LIPUS treatment

LIPUS (+): both radius and ulna diaphysis fracture group treated with LIPUS stimulation

Flex: flexion, Ext: extension, Pro: pronation, Sup: supination.

average \pm SD

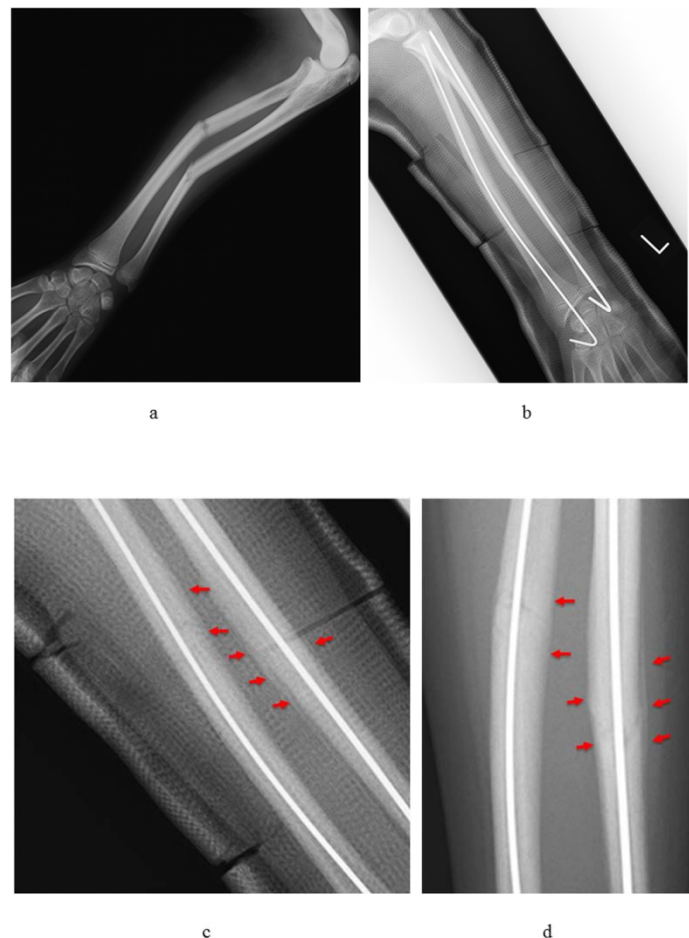


Figure 1: Radiographs from a patient in the LIPUS-treated group.

- a. A case of 11-year-old female who suffered both radius and ulna diaphysis fractures.
- b. A radiograph taken at 2 weeks after operation. The radius and ulna fracture are pinned with a single K-wire from the radial styloid and ulnar head to the shaft.
- c. Enlargement of the Fig. 2b. Periosteal calluses (arrows) in both the radius and ulna are observed in the cast.
- d. Bridging bone over the fractured cortices (arrows) has matured at 4 weeks after treatment and pins are removed.

vascular and tendon injuries, were observed. Periosteal callus formation appeared as early as 1-2 weeks after surgery in the LIPUS-stimulation groups, which was confirmed even in the cast, and it had matured to form bone bridging over the fractured cortices (Figure 1). The duration of cast immobilization, time needed for callus appearance and bone union, timing of pin removal, number of cases whose reduced position displaced after pin removal and observation period after surgery are summarized in Table 2. The time spans needed for callus appearance and bone union in the patients with LIPUS stimulation were significantly shorter than that in the

patients without LIPUS stimulation. There was a tendency that duration of pinning and cast immobilization was shorter in the group with LIPUS treatment compared without LIPUS treatment. Useful functional recovery was obtained in wrist extension and flexion, as well as forearm pronation and supination in each fracture group, and there were no significant differences between the patients with and without LIPUS stimulation (Table 3).

Discussion

Because fracture healing of the distal radius only is easily attainable with percutaneous pinning and cast immobilization in children, LIPUS stimulation may not be needed post-operatively. However, intraosseous blood circulation in the mid-diaphysis of ulna, termed the “watershed-zone” in a previous study [6], can be easily disturbed. Furthermore, treatment period of the unstable fracture including both radius and ulna takes a long time and re-displacement can occur easily after reduction in the cast. Therefore, intramedullary nailing with the K-wire followed by application of LIPUS therapy in the fractures of both radius and ulna diaphysis is expected to be beneficial for facilitating new bone maturation, fracture healing and prevention of malunion. In this study, the early callus appearance with LIPUS stimulation resulted in early bone union compared with the group without LIPUS stimulation. Furthermore, the period of pinning and cast immobilization tended to be shorter and the number of cases of malunion was smaller in the LIPUS-treated group compared with non-LIPUS-treated group. These results may support the hypothesis that LIPUS stimulation can lead to a reduction of treatment periods of unstable forearm fractures even in children. It is certain that useful functional recovery was definitely obtained in each fracture group, with and without LIPUS therapy. However, these findings can be explained by the fact that the period of cast immobilization was as short as 4-5 week even in the group without LIPUS treatment, and the large tolerability of joint contracture in children due to their prominent joint plasticity.

References

1. Fernandez FF, Egenolf M, Carsten C, Holz F, Schneider S, et al. (2005). Unstable diaphyseal fractures of both bones of the forearm in children: plate fixation versus intramedullary nailing. *Injury*. 36: 1210–1216.
2. McKibbin B. (1978). The biology of fracture healing in long bones. *J Bone Joint Surg Br*. 60-B: 150-162.
3. Lascombes P, Prevot J, Ligier JN, Metaizeau JP, Poncelet T. (1990). Elastic stable intramedullary nailing in forearm shaft fractures in children: 85 cases. *J PediatrOrthop*. 10: 167–171.
4. Ono M, Bechtold JE, Merkow RL, Sherman RE, Gustilo RB. (1989). Rotational stability of diaphyseal fractures of the radius and ulna fixed with Rush pins and/or fracture bracing. *ClinOrthopRelat Res*. 240: 236–243.
5. Adamczyk MJ, Riley PM. (2005). Delayed union and nonunion following closed treatment of diaphyseal pediatric forearm fractures. *J PediatrOrthop*. 25: 51–55.
6. Wright TW, Glowczewskie F. (1998). Vascular anatomy of the ulna. *J Hand Surg Am*. 23: 800–804.
7. Pounder NM, Harrison AJ. (2008). Low intensity pulsed ultrasound for fracture healing: a review of the clinical evidence and the associated biological mechanism of action. *Ultrasonics*. 48: 330-338.
8. Grigoryan M, Lynch JA, Fierlinger AL, Guermazi A, Fan B, et al. (2003). Quantitative and qualitative assessment of closed fracture healing using computed tomography and conventional radiography. *AcadRadiol*. 10: 1267-1273.