

# Potentially Fatal Complication of Luxatio Erecta: Case Report and Evidence Based Literature Review

Mariano Lopez-Franco<sup>1,2\*</sup>, Patricia Morales Munoz<sup>1</sup>, Teresa Munoz Sicilia<sup>1</sup>

<sup>1</sup>Orthopaedic Surgery Department, Hospital Infanta Sofia, Spain

<sup>2</sup>Orthopaedic Surgery Department, South Hospital of Alcorcon, Spain

## ARTICLE INFO

### Article history:

Received: 16 April 2018

Accepted: 26 May 2018

Published: 12 June 2018

### Keywords:

Shoulder dislocation;

Luxatio erecta;

Pseudoaneurysm;

Axillary artery

**Copyright:** © 2018 Lopez-Franco M et al., Ann Orthop Trauma Rehabil  
This is an open access article distributed under the Creative Commons Attribution License, which permits unrestricted use, distribution, and reproduction in any medium, provided the original work is properly cited.

**Citation this article:** Lopez-Franco M, Munoz PM, Sicilia TM. Potentially Fatal Complication of Luxatio Erecta: Case Report and Evidence Based Literature Review. Ann Orthop Trauma Rehabil. 2018; 2(1):120.

### Correspondence:

Mariano Lopez-Franco,  
Department of Orthopedic  
Surgery and Traumatology,  
Infanta Sofia Hospital, Spain,  
Tel: +34 911 91 40 00,  
Email: lopezfranco\_cot@yahoo.es

## ABSTRACT

Inferior shoulder dislocation or luxatio erecta is one of the less usual forms of shoulder dislocation. Musculoskeletal and neurovascular injuries are frequently associated. Injury of the axillary artery causing pseudoaneurysm is a very rare occurrence but it is a serious surgical emergency and a surgical intervention is indicated. Misdiagnosis or delayed diagnosis of axillary pseudoaneurysm may result in upper limb morbidity or patient mortality.

### Introduction

Inferior subtype or luxatio erecta constitutes 0.5% of all shoulder dislocation [1,2] and have been associated with fractures, vascular, neurologic, tendinous and ligamentous injuries [3,4]. The vascular injuries are very rare complications after a shoulder dislocation but it could result in severe consequences even life-threatening. The highest incidence reported of significant vascular compromise associated to shoulder dislocation has been in cases of luxatio erecta [3].

Pseudoaneurysms due to musculoskeletal trauma are rare and comprise less than 2% of all pseudoaneurysms [5]. An acute hemorrhage may become apparent at the time of closed reduction of a shoulder dislocation but, more often, the diagnosis is delayed by days, weeks, or even years due to variable clinical signs and the lack of suspicion for vascular injuries [6].

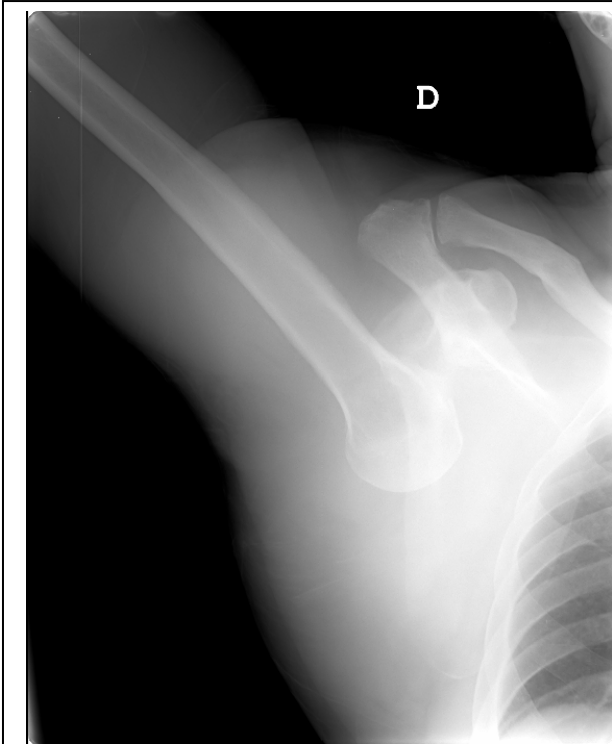
We describe in this paper a case of axillary artery pseudoaneurysm following an inferior shoulder dislocation in a 73-years-old man without penetrating trauma who developed brachial plexus palsy ten days after the dislocation. In addition, a broad review of the literature of this unusual complication was conducted. It is aimed at raising the index of suspicion for identifying this life-threatening injury.

### Case report and Methods

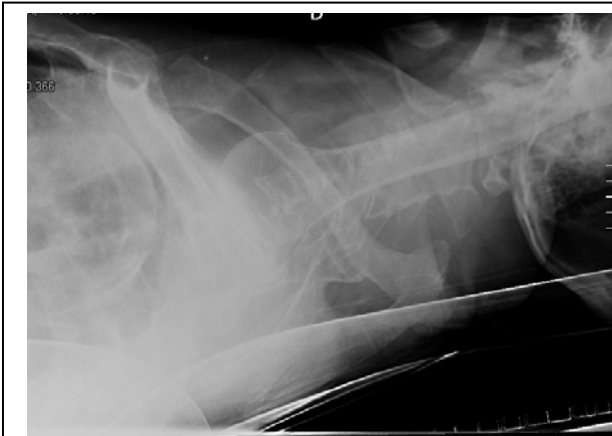A 73-years-old right-handed man was taken to the emergency department of our hospital after a casual fall out of his bed whereas he was sleeping.

He presented with his right arm over his head supported with his left hand. The distal pulses were present. The accurate neurological examination was difficult because of severe pain, but he complained of anesthesia in his right hand and

he was no able to extend his right wrist. Initial x-rays of his right shoulder showed an inferior glenohumeral dislocation (Figures 1,2).



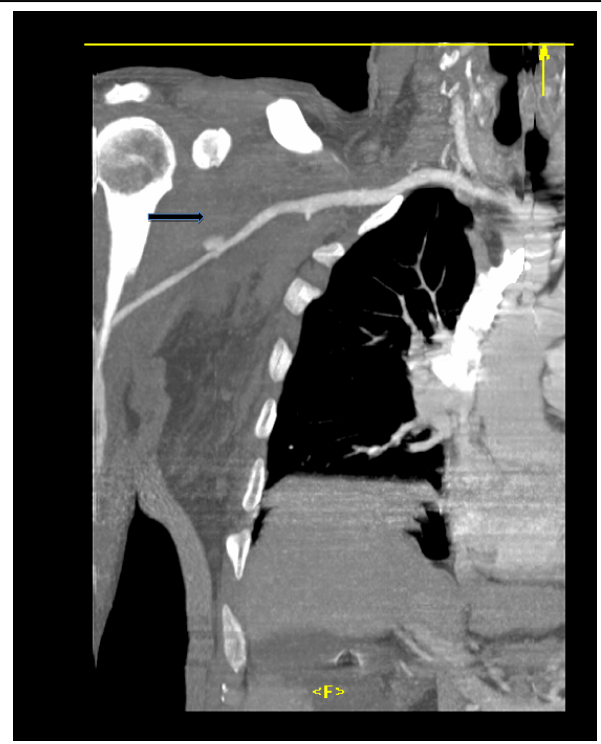
**Figure 1:** X-ray showing right shoulder inferior glenohumeral dislocation (AP view).



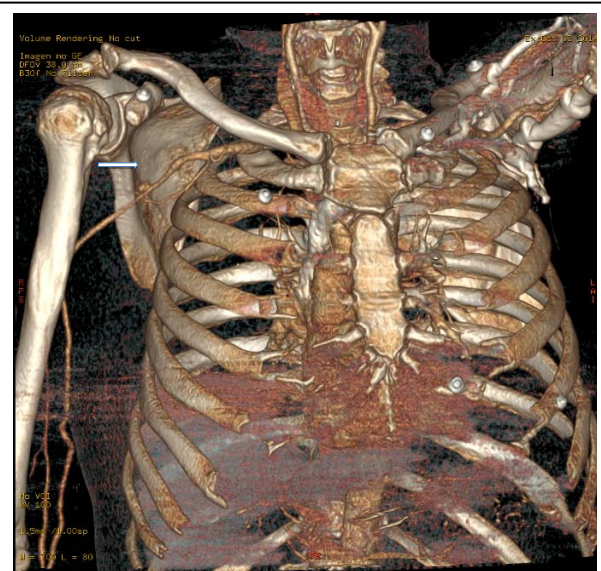
**Figure 2:** X-ray showing right shoulder inferior glenohumeral dislocation (axillary view).

Closed reduction under deep sedation, using intravenous propofol, was achieved applying the traction-countertraction technique in the operating room. After shoulder reduction the peripheral pulses were open but signs of brachial plexus damage were observed.

In order to evaluate neurological damages observation in the hospital was recommended. Two days after the injury, the neurological examination was not normal with



**Figure 3:** A pseudoaneurysm of the axillary artery (arrow) was diagnosed with an urgent computed tomography angiography



**Figure 4:** Computed tomography angiography reconstruction showing the pseudoaneurysm (arrow).

palsy of the axillary nerve and strength testing 4/5 in his right hand, wrist and elbow and persistent numbness in his hand and forearm (mainly in the radial nerve, but also in the ulnar and median nerves distributions). The

patient needed urinary catheterization because of an acute urinary retention during a week and he did not was discharged from the hospital because of social problems.

Ten days after the dislocation the patient complained of progressive neurological deficit. He scored 10 of 10 using a visual analogue scale for pain.

**Table 1:** Cases of axillary pseudoaneurism after shoulder dislocation.

First Author	Year	Type of dislocation	Delayed diagnosis	Complications
	1975	Anterior	6 months	No
Fitzgerald (19)	1980	Anterior	1 month	Posterior cord of the brachial plexus (FU:5 years)
Drury (20)	1980	Anterior	N.D.	N.D.
Pieliński (21)	1984	Anterior	6 weeks	Brachial plexus palsy (FU:18 months)
Gallen (22)	1985	Anterior	6 weeks	N.D.
Majeed (23)	1986	Anterior	N.D.	N.D.
Stein (24)	1989	Anterior	2 weeks	Weakness of finger extension (FU: 1 year)
Bhamra (25)	1994	Anterior	3 weeks	Brachial plexus paresthesia (recovered at FU:16 months)
Oberwalder (26)	1994	Anterior	N.D.	N.D.
Zieren (27)	1994	Anterior	5 months	Death after biopsy
Schiwy-Bochat (28)	1996	Anterior	N.D.	N.D.
Gaspar (29)	1996	Anterior	N.D.	Carotid dissection
Edmunds (30)	1996	Anterior	2 years	No
Orecchia (31)	1996	Anterior	3 weeks	Axillary nerve dysfunction (no follow up)
Emadian (32)	1997	Anterior	10 days	Lower trunk at 1 year
Escuder (33)	1998	Anterior	10 days	No
Babatasi (34)	1998	Anterior	Few hours	N.D.
Juliá (35)	1999	Anterior	2 weeks	No
Monteleone (36)	2001	Anterior	30 days	Unspecified neurological complications (no recovered)
Aerst (37)	2002	Anterior	5 months	Almost complete axonotmesis of the brachial plexus
Helm (16)	2006	Anterior	2 weeks	Posterior cord palsy of the brachial plexus
McCann (38)	2006	Anterior	2 weeks	No
Stahnke (5)	2007	Anterior	8 weeks	Neuropraxia of his left brachial plexus
Whittam (39)	2009	Anterior	3 weeks	EMG: severe damage to the axillary and radial nerve. Minor damage to the medial nerve (FU:No neurological improvement)
Te Slaa (40)	2010	Anterior	2 months	Brachial plexus palsy
Karkos (41)	2010	LE	3 days	Median, ulnar and radial nerve function was absent. Completely recovered
Plaga (42)	2011	Anterior	2 months	Brachial plexus palsy
Gasparini (43)	2012	Anterior	10 months	No
Palcau (44)	2013	Anterior	4 months	No
Nour (45)	2014	LE	N.D.	Complete sensory-motor deficit of the forearm and the hand. Completely recovered one year later
Iakovlev (8)	2015	Anterior	6 months	No
Sannananja (46)	2017	Anterior	7 days	Brachial plexus palsy
Schumann (47)		LE	10 days	Posterior cord of the brachial plexus (FU:15 months)

LE: Luxatio erecta; EMG: Electromyography; N.D: non defined or unknown; FU: follow-up

He was not able to extend fingers, wrist nor right elbow, the peripheral pulses were palpable but a large pectoral haematoma, not previously seen, was observed. We suspected a vascular injury and a pseudoaneurysm of the axillary artery was diagnosed by an urgent computed tomography (Figures 3,4). The patient was moved to the nearest hospital with an available vascular surgeon, where he was successfully treated by stent graft placement through the brachial artery with an excellent angiographic result. Despite the technical success, serious neurological impairment persisted after the procedure. Neurophysiological studies were performed one year later and revealed a slight damage of the posterior cord of the brachial plexus and mild of the medial cord. At the last follow-up, fifteen months after the dislocation, the patient claimed numbness in his right hand. He didn't have recovered the strength and showed brachial plexus damage with strength 4/5 to extend his wrist backward and weakness in his right hand. The Disabilities of the Arm Shoulder and Hand (DASH) symptom scale was used to evaluate the patient. At the follow-up the patient rated 110 points according to the DASH scale.

A search of the Medline, Cochrane, EMBASE and Google Scholar on February 28, 2018 in order to identify cases of axillary pseudoaneurysm due to non-complicated shoulder dislocation was performed. We considered a non-complicated dislocation whenever this was non-penetrating and it was not associated to a fracture. We founded thirty-two cases, two of them occurred after an inferior shoulder dislocation (Table 1).

## Discussion

Luxatio erecta is an infrequent type of shoulder dislocation [1-3] and it is important mastering the accurate maneuvers of reduction. Moreover, vascular complications resulting from shoulder dislocation are rare [3,7,8] but potentially fatal, so lack of awareness regarding this complication could result in severe consequences.

Although luxatio erecta humeri have been recognized since 1859 [9] very few reports have been published to date [1-3,10,11]. Davids reported two mechanisms of

luxatio erecta [12]. The most usual is the indirect mechanism, typically due to violent abduction force on an already abducted limb so that the proximal shaft of the humerus is levered over the acromion. In this scenario, the humeral head breaks the inferior joint capsule and the inferior and middle glenohumeral ligament. The other one is the direct mechanism, which occurs after direct axial loading on a fully abducted arm.

The most commonly described closed reduction maneuver for inferior shoulder dislocation involves overhead traction with the hyperabducted arm usually performed with an assistant to provide countertraction [13]. Nho described a two-step technique that first converts the inferior dislocation to an anterior dislocation [4]. A case of luxatio erecta with concomitant surgical neck fracture described difficulty with the overhead traction-countertraction method, but when the author used direct manipulation over the humeral head with his fist, he was able to reduce the inferiorly dislocated humeral head [14].

Mallon [3] reviewed 80 cases of luxatio erecta. They found that either a fracture of the greater tuberosity or a rotator cuff tear was associated with this injury in 80% of patients and 60% sustained some degree of neurologic compromise, most commonly to the axillary nerve. Only 3.3% of the cases demonstrated significant vascular compromise, but this is the highest incidence for any shoulder dislocation.

Vascular injuries after shoulder dislocation are extremely rare but potentially life-threatening. Gates [15] reviewed the English literature between 1956 and 1995 and found only 22 cases of anterior dislocation with axillary artery injury. Helm reviewed the English literature from 1995 to 2002 and he only found 2 further cases [16].

Pseudoaneurysms due to musculoskeletal trauma are rare [5]. An acute hemorrhage may become apparent at the time of closed reduction of a shoulder dislocation but, more often, the diagnosis is delayed by days, weeks, or even years due to variable clinical signs and the lack of suspicion for vascular injuries [6].

Injury to the axillary should be considered anytime a brachial plexus injury has been identified. If suspicion is high, angiography is indicated [17]. Furthermore, vascular injuries occur most frequently in the elderly population due to the loss of arterial elasticity secondary to atherosclerosis. Over 90% of reported cases of vascular injury following shoulder dislocation occur in patients over the age of 50 [7] and 75% of cases involve patients aged 60 or older [18]. Brachial plexus paralysis was diagnosed in our 73-years-old patient, but he did not undergo any specific vascular study until two weeks after the dislocation.

In a review of the literature from 1947 to 1975 only one report of pseudoaneurysm of the axillar artery after uncomplicated shoulder dislocation was founded [19]. Since then, we have found 31 more cases reported in the literature, two of them following luxatio erecta of the shoulder (Table 1) [5,8,16,19-47]. Besides, some cases of luxatio erecta associated with axillary artery injuries have been reported [48,49]. Seeing as pseudoaneurysm of the axillar artery is uncommon complication this injury may be overlooked, so the clinical index of suspicion for this diagnosis should be high. Likewise, because of the higher degree of vascular compromise seen with luxatio erecta compared with other shoulder dislocations [17], it is recommended that any patient who presents with luxatio erecta should be extensively observed in order to avoid late complications. If there is any indication of a vascular problem, an immediate arteriogram is indicated [3]. Clinical diagnosis is often difficult because muscle spasm prevents adequate examination and distal pulses may be preserved because of good collateral circulation. There is often a delay of weeks to years after the trauma before the pseudoaneurysm presents [16,19,20,28,31,37,39,43,44]. As the pseudoaneurysm grows, symptoms become more apparent due to the close proximity of the neural and other vascular structures in the axilla. Compression of nervous bundles and venous structures causes neuropathy and venous obstruction and thrombosis [16].

Although endovascular treatment of these lesions could seem attractive, open surgical techniques could allow us

to treat frequent concomitant injuries and perform decompression of the axillary fossa because of the large haematoma [35]. Our patient underwent an endovascular approach and he did not recover his neurologic deficits. A direct comparison between open or endovascular management of these lesions would be interesting but is beyond the scope of this paper.

## Conclusions

Elderly patients such as the patient described in this paper have a high susceptibility to axillary arterial injury following trauma such as shoulder dislocation, due to the loss of arterial elasticity and the infrequent type of shoulder dislocation suffered. Delayed recognition of these lesions, such as in our case, may lead to permanent neurologic deficits despite adequate vascular repair of the axillary artery [16,20,22,33,38,41,43], upper-limb morbidity or patient mortality [28,30]. So, in elderly patients suffering of luxatio erecta maybe a deep vascular study is mandatory.

## Acknowledgments

The authors thank Dr Murciano and Dr Gebhard for their help with the translation of reviewed literature. We also thank our patient because without his authorization we would not have written this article.

## References

1. Goldstein JR, Eilbert WP. (2004). Locked anterior-inferior shoulder subluxation presenting as luxatio erecta. J Emerg Med. 27: 245-248.
2. Garcia R, Ponsky T, Brody F, Long J. (2006). Bilateral luxatio erecta complications by venous thrombosis. J Trauma. 60: 1132-1134.
3. Mallon WJ, Bassett FH 3rd, Goldner RD. (1990). Luxatio erecta: the inferior glenohumeral dislocation. J Orthop Trauma. 4: 19-24.
4. Nho SJ, Dodson CC, Bardzik KF, Brophy RH, Domb BG, et al. (2006). The two-step maneuver for closed reduction of inferior glenohumeral dislocation (luxatio erecta to anterior dislocation to reduction). J Orthop Trauma. 20: 354-357.
5. Stahnke M, Duddy MJ. (2006). Endovascular repair of a traumatic axillary pseudoaneurysm following



- anterior shoulder dislocation. *Cardiovasc Intervent Radiol*. 29: 298-301.
6. Capello T, Gordon WN, Kevin DN, McCarthy WJ. (1996). Acute ischemia of the upper limb fifteen years after anterior dislocation of the glenohumeral joint and a modified Bristow procedure. A case report. *J Bone Joint Surg Am*. 78: 1578-1582.
  7. Kelley SP, Hinsche AF, Hossain JF. (2004). Axillary artery transection following anterior shoulder dislocation: classical presentation and current concepts. *Injury*. 35: 1128-1132.
  8. Iakovlev M, Marchand JB, Poirier P, Bargoin K, Goueffic Y. (2014). Posttraumatic axillary false aneurysm after luxatio erecta of the shoulder: case report and literature review. *Ann Vasc Surg*. 28: 1321.
  9. Middeldorpf M, Scharm B. (1859). De Nova Humeri Luxationis Specie. In: *Clinique Européenne* 2. Dissert Inag, Breslav, Poland.
  10. Laskin RS, Sedlin ED. (1971). Luxatio erecta in infancy. *Clin Orthop Relat Res*. 80: 126-129.
  11. Yamamoto T, Yoshiya S, Kurosaka M, Nagira K, Nabeshima Y. (2003). Luxatio erecta (inferior dislocation of the shoulder): a report of 5 cases and a review of the literature. *American Journal of Orthopedics*. 32: 601-603.
  12. Davids JR, Talbott RD. (1990). Luxatio erecta humeri. A case report. *Clin Orthop Relat Res*. 252: 144-149.
  13. Rockwood CA, Wirth MA. (1996). Subluxations and dislocations about the glenohumeral joint. In: Rockwood CA, Green DP, Bucholz RW, et al, eds. *Fractures in Adults*. Philadelphia: Lippincott-Raven. 1193-1339.
  14. Tomcovcik L, Kitka M, Molcanyi T. (2004). Luxatio erecta associated with a surgical neck fracture of the humerus. *J Trauma*. 57: 645-647.
  15. Gates JD, Knox JB. (1995). Axillary artery injuries secondary to anterior dislocation of the shoulder. *J Trauma*. 39: 581-583.
  16. Helm AT, Watson JS. (2002). Compression of the brachial plexus in a patient with false aneurysm of the axillary artery as a result of anterior shoulder dislocation. *J Shoulder Elbow Surg*. 11: 278-279.
  17. Beeson MS. (1999). Complications of shoulder dislocation. *Am J Emerg Med*. 17: 288-295.
  18. Allie B, Kilroy DA, Riding G, Summers C. (2005). Rupture of axillary artery and neuropraxis as complications of recurrent traumatic shoulder dislocation: case report. *Eur J Emerg Med*. 12: 121-123.
  19. Fitzgerald JF, Keates J. (1975). False aneurysm as a late complication of anterior dislocation of the shoulder. *Ann Surg*. 181: 785-786.
  20. Drury JK, Scullion JE. (1980). Vascular complications of anterior dislocation of the shoulder. *Br J Surg*. 67: 579-581.
  21. Pielinski M, Mikolajewski J. (1980). (Pseudoaneurysm of the axillary artery after shoulder dislocation). *Chir Narzadow Ruchu Ortop Pol*. 45: 415-417.
  22. Gallen J, Wiss DA, Cantelmo N, Menzoin JO. (1984). Traumatic pseudoaneurysm of the axillary artery: report of three cases and literature review. *J Trauma*. 24: 350-354.
  23. Majeed L. (1985). Pulsatile haemarthrosis of the shoulder joint associated with false aneurysm of the axillary artery as a late complication of anterior dislocation of the shoulder. *Injury*. 16: 566-567.
  24. Stein E. (1986). Case report 374: Post-traumatic pseudoaneurysm of axillary artery. *Skeletal Radiol*. 15: 391-393.
  25. Bhamra M, Ferris BD, Paton DF. (1989). Axillary aneurysm after shoulder injury. A report of 2 cases. *Acta Orthop Scand*. 60: 225-226.
  26. Oberwalder M, Thöni H, Brugger M, Pointner R. (1994). Das traumatische Arteria-axillaris-Aneurysma, eine seltene und ernste Komplikation der vorderen Schulterluxation (Traumatic aneurysm of the axillary artery, a rare and severe complication of anterior shoulder dislocation). *Chirurg*. 65: 1056-1058.
  27. Zieren J, Kasper A, Landwehr P, Erasmi H. (1994). Traumatic pseudoaneurysm of the axillary artery after shoulder dislocation. *Chirurg*. 65: 1058-1060.

28. Schiwy-Bochat KH. (1994). Iatrogenic fatal outcome of traumatic axillary artery aneurysm. *Int J Legal Med.* 107: 96–98.
29. Gaspar M, Petrescu LP, Fluture V, Dragulescu I, Cosma O, et al. (1996). [Posttraumatic pseudoaneurysm of the axillary artery after anterior dislocation of the shoulder: a case report]. *Chirurgia (Bucur).* 45: 317-320.
30. Edmunds I, Tonkin MA. (1996). Brachial plexus palsy and carotid artery dissection. *J Hand Surg Br.* 21: 695.
31. Orecchia PM, Calcagno D, Razzino RA. (1996). Ruptured axillary pseudoaneurysm from chronic shoulder dislocation. *J Vasc Surg.* 24: 499-500.
32. Emadian SM, Lee WW. (1996). Axillary artery pseudoaneurysm and axillary nerve palsy: delayed sequelae of anterior shoulder dislocation. *Am J Emerg Med.* 14: 108-109.
33. Escuder Capafons MC, Monllau García JC, Ballester Soleda J. (1997). Paralysis of the brachial plexus by pseudoaneurysm of the axillary artery after shoulder dislocation. *Journal of Osteoarticular Surgery.* 32: 274-276.
34. Babatasi G, Massetti M, Le Page O, Theron J, Khayat A. (1998). Endovascular treatment of a traumatic subclavian artery aneurysm. *J Trauma.* 44: 545-547.
35. Julia J, Lozano P, Gomez F, Corominas C. (1998). Traumatic pseudoaneurysm of the axillary artery following anterior dislocation of the shoulder. Case report. *J Cardiovasc Surg (Torino).* 39: 167-169.
36. Monteleone G, Zareh A, Marconi A, Oliva F, Palombi M. (1999). Post – traumatic Pseudoaneurysms of the axillary artery: a rare and unexpected complication from anterior dislocation of the shoulder. Case report. *Progress reports.* 11: 25-31.
37. Aerts NR, De Paula e Silva E, Diez Paiva H. (2001). (Pseudoaneurysm of axillary artery after anterior shoulders dislocation: a case report and review of literature). *Cir. vasc. Angiol.* 17: 27-31.
38. McCann PA, Barakat MJ, Wand JS. (2006). Delayed brachial plexus compression secondary to anterior shoulder dislocation - The late consequence of an axillary artery pseudoaneurysm: A case report. *Injury Extra.* 37: 458-461.
39. Whittam K, Hardy M. (2007). A case study of an axillary artery pseudoaneurysm following anterior dislocation of the glenohumeral joint: A rare presentation on plain film radiographs. *Radiography.* 13: 221-228.
40. Te Slaa A, Vos D, Geenen G, Dolmans D, Van der Laan L. (2009). Endovascular Treatment of an Axillary Pseudoaneurysm Following a Traumatic Shoulder Dislocation. *Eur J Trauma Emerg Surg.* 35: 417.
41. Karkos CD, Karamanos DG, Papazoglou KO, Papadimitriou DN, Zambas N, et al. (2010). Axillary artery transection after recurrent anterior shoulder dislocation. *Am J Emerg Med.* 28: 119.
42. Plaga BR, Looby P, Feldhaus SJ, Kreutzmann K, Babb A. (2010). Axillary artery injury secondary to inferior shoulder dislocation. *J Emerg Med.* 39: 599-601.
43. Gasparini M, Jakomin T. (2011). Endovascular treatment of an Axillary Artery Pseudoaneurysm after Anterior Shoulder Dislocation: A Case Report. *Zdravniški Vestnik.* 80: 422-426.
44. Palcau L, Gouicem D, Dufranc J, Mackowiak E, Berger L. (2012). Delayed axillary artery pseudoaneurysm as an isolated consequence to anterior dislocation of the shoulder. *Ann Vasc Surg.* 26: 279e9-e12.
45. Nour M, Zerhouni H, Bensaid B, Khaloufi S, Ouazzani L, et al. (2013). (Axillary artery pseudoaneurysm secondary to shoulder dislocation in children). *J Mal Vasc.* 38: 377-380.
46. Sannananja B, Shah HU, Laxman V, Nagesh C. (2015). PVNS or pseudo aneurysm: MRI-problem solving or misleading? *Indian J Radiol Imaging.* 25: 60-62.
47. Schumann DR, Superti MJ, Seyboth FC, Jacomet GE. (2017). Brachial plexus injury secondary to pseudoaneurysm of axillary artery after glenohumeral dislocation: case report. *Rev Bras Ortop.* 52: 491-495.

48. Gardham JR, Scott JE. (1979). Axillary artery occlusion with erect dislocation of the shoulder. Injury. 11: 155-158.
49. Lev-El A, Adar R, Rubinstein Z. (1981). Axillary artery injury in erect dislocation of the shoulder J Trauma. 21: 323-325.