

## Plate Fixation of Posterior Malleolar Fractures through Posterolateral Approach

El-Sebai M\*, Emran A, El-Sayed M and Saeid MS

Department of Orthopedic Surgery, Tanta University, Egypt

### ARTICLE INFO

Received Date: May 16, 2019

Accepted Date: June 20, 2019

Published Date: June 22, 2019

### KEYWORDS

Posterolateral approach

Posterior malleolus

Plate fixation

**Copyright:** © 2019 El-Sebai M et al., Annals Of Orthopaedics, Trauma And Rehabilitation. This is an open access article distributed under the Creative Commons Attribution License, which permits unrestricted use, distribution, and reproduction in any medium, provided the original work is properly cited.

**Citation for this article:** El-Sebai M, Emran A, El-Sayed M and Saeid MS. Plate Fixation of Posterior Malleolar Fractures through Posterolateral Approach. Annals Of Orthopaedics, Trauma And Rehabilitation. 2019; 2(1):130

### Corresponding author:

Mostafa El-SebaiFarrag

Demonstrator of Orthopedic Surgery,  
Department of Orthopedic Surgery,  
Faculty of Medicine, Tanta University,  
36 Saeedst, Tanta, Egypt; Tel:+20  
1069966233;

Email:

mostafa.elsebai@med.tanta.edu.eg,

Most.els.hammad@gmail.com

### ABSTRACT

**Background:** Posterior malleolar fractures are intra-articular, and can jeopardize the strength of the syndesmotic ligaments, with most of the literature noting the need for fixation when fragments are larger than 20%, however, there is no agreement on the best method for fixation. The purpose is to evaluate the clinical, functional, and radiological outcome of plate fixation of posterior malleolus using posterolateral approach

**Methods:** 15 patients with posterior malleolar fractures (as a part of SER 3 or SER 4) that was larger than 20% underwent plate fixation of posterior malleolus through posterolateral approach, lateral malleolus (when involved), were fixed by posterior antiglide plate through the same incision, medial malleolus (when fractured) was fixed using a separate medial incision, assessment was done by a modified Baird and Jackson score.

**Results:** 12 cases achieved satisfactory results (five excellent-seven good), two cases had fair outcome, and one case with poor outcome as a result of developing post traumatic arthritis, no cases had deep wound infection, no posterior malleolar malreduction or loss of reduction

**Conclusion:** directly visualizing the fracture fragment, performing anatomical reduction and rigid fixation, with minimal wound complication, all represent the advantages of fixation of posterior malleolar fracture through Posterolateral approach, thus, it offers a safe and good alternative to the traditional AP screw fixation.

### INTRODUCTION

Malleolar ankle fractures represent 9-10% of all fractures, and Posterior malleolar injuries are usually a part of bimalleolar or trimalleolar fractures, while rare to occur in isolation (0.5% to 1%) [1]. In addition to being intra-articular, Posterior malleolar fractures jeopardize the strength of the syndesmotic joint [1]. In a cadaveric study, Ogilvie-Harris et al., [2] showed that 42% of syndesmotic stability is provided by the posterior inferior tibio-fibular ligament, indicating the significance of the posterior malleolus in syndesmotic and ankle stability. Fixation of posterior malleolar fracture is generally indicated with fragment size ranging from 20% to 33% of tibial plafond. Different operative techniques exist for posterior malleolar fixation, as indirect reduction and Anteroposterior (AP) screw fixation, which is the most common method of fixation among orthopedic surgeons and at our hospital, however, this doesn't offer the assurance of accurate reduction, especially with soft tissue interposition,

comminution, loose fragments, and added difficulty in assessing anatomical reduction using image intensifier alone. Other techniques are direct postero-anterior screw fixation, and buttress plate. However, there is no consensus on the best method for posterior malleolar fixation [3-6].

## OBJECTIVES

Evaluation of the clinical, functional, and radiological outcome of plate fixation of posterior malleolar fractures using posterolateral approach

## Patients and methods

In this prospective study, 15 patients were presented with closed posterior malleolar fracture, 4 of which were males, 11 were females. Age ranged from 28 to 59 with mean of 46.13 years. Fractures treated in this study were Supination External Rotation (SER) 3 and 4 according to the Lauge-Hansen's classification [7], 12 cases had twisting injury, and 4 cases had Motor Vehicle Accident as the causative trauma. They were presented to our academically supervised hospital in the period between August 2017 and August 2018. They were treated operatively with plate fixation of posterior malleolar fracture through posterolateral approach. Inclusion criteria were posterior malleolar fractures involving more than 20% articular surface, closed fracture or those of Gustilo-Anderson type I [8], and occurring in adults (after physal closure). Exclusion criteria were open fractures (Gustilo-Anderson type [8] II or III), neurovascular injury, bad skin and soft tissues condition in the posterolateral aspect of the ankle, pathological fractures, pediatric age (before physal closure) and those with mental impairment or those who are unable to communicate. Ankle AP, lateral and mortise views were obtained to delineate injury, CT was also obtained in all cases to evaluate the size, site, and number of fragments. Fracture was splinted with below knee posterior slab until the time of operation. Surgery was delayed (about a week) in the presence of severe soft tissue swelling or skin blisters, to allow improvement of the soft tissue condition and for the "wrinkle sign" to appear, this was required in two cases. Approval for the study was obtained from the Faculty of Medicine Research Ethics Committee. Full counseling of participants in this research and informed consent was obtained from all patients prior to participation, with full privacy of participants and confidentiality of their data preserved.

## Surgical procedure

-Preoperative I.V antibiotics (Ampicillin\Sulbactam) were given 30 min to one hour before surgery.

-Position: using a radiolucent table, while supine, the limb was exsanguinated by elevation for three to five minutes, and then a tourniquet was applied around the thigh. The position was then changed into prone position with the knee flexed around 20° (Figure 1), the ankle was placed over a small bump to allow the foot to be hanging free over the bump, so that gravity aids reduction of any displaced posterior fragment rather than being an opposing force as when in supine position. Skin incision was made midway between the posterior aspect of the lateral malleolus and the lateral border of Achilles tendon (Figure 2), extending from the tip of the lateral malleolus as far proximally as required. The sural nerve and the small saphenous vein were pursued under the superficial fascial layer and included in the lateral flap (Figure 3).

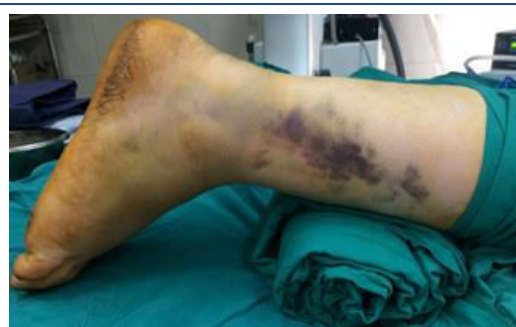

Figure 1: position of the patient.

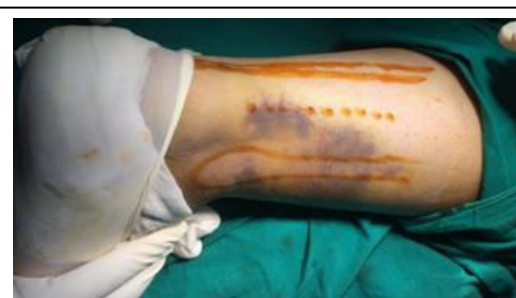

Figure 2: Landmarks (midway between lateral malleolus and Achilles tendon).

However, the sural nerve was not always encountered, as it usually runs just behind the lateral malleolus, well anterior to the incision [9]. Exposure of the posterior aspect of the tibia was done through an interval between the peronei laterally - supplied by the superficial peroneal nerve- and the Flexor

Hallucis Longus (FHL) medially -supplied by the tibial nerve-, FHL was recognizable by moving the great toe and also by being fleshy till the distal part of tibia.

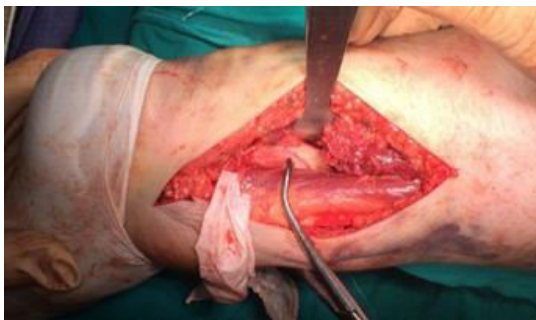

Figure 3: The sural nerve and the small saphenous vein.

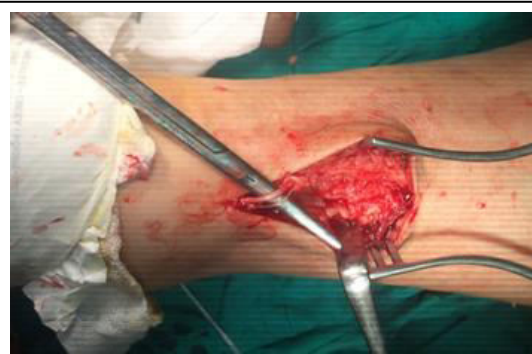

Figure 4: Holding the reduction using pointed reduction clamp.

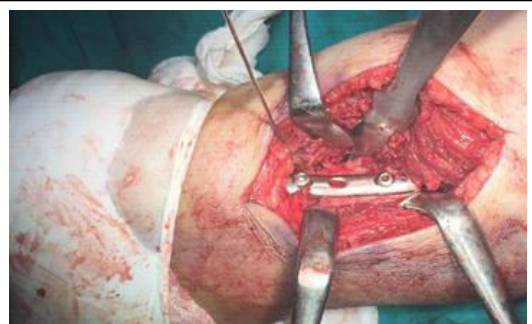


Figure 5: Placement of the plate.

FHL was then stripped off the bone, starting from the fibula, down to the interosseous membrane, and the rest of the deep posterior compartment was elevated off the posterior tibia, the entire posterior aspect of the tibial surface was then exposed by retracting this muscle medially (Figure 4). This also provided protection for the posteromedial neurovascular bundle. Loose

fragments and debris between fragments were removed; proximal displacement of the posterior malleolus was reduced by axial and anterior traction on the foot. The fracture was reduced anatomically under direct vision, using the edges and the apex of the fracture line as a guide, The fragment was fixed by placing a posterior antiglide plate (one-third tubular plate) with under contouring to provide a satisfactory buttress effect, the nearest screw to the fracture proximally was the first to be placed, screws were also placed in the fragment through the plate if the fragment was of sufficient size (Figure 5), internal rotation of the foot around 15 degrees during placement of the screws helped to achieve more accurate trajectory .The plate position, screws and accuracy of the reduction were checked using image intensification (Figure 6).

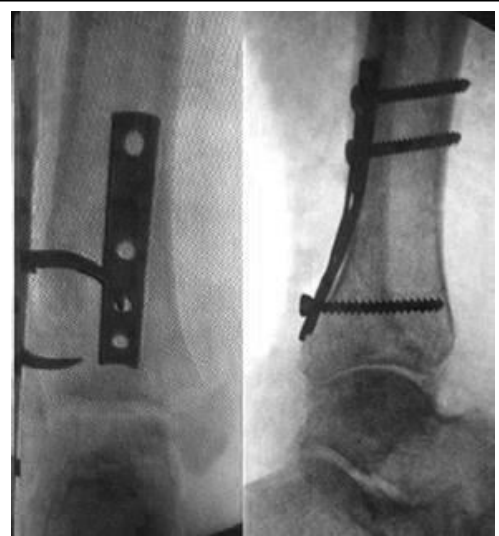

Figure 6: Checking plate position using image intensification.

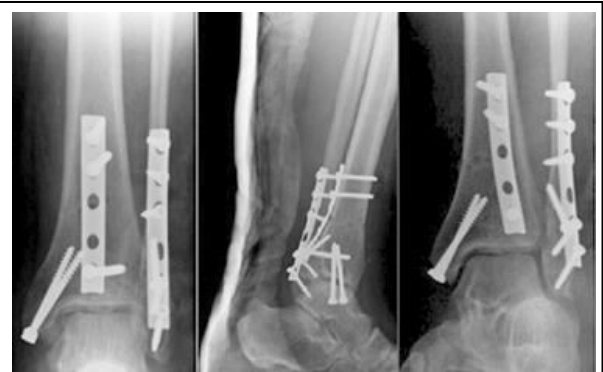

Figure 7: post-operative X-rays

The peroneal muscles were then retracted medially to expose the fibula, which was then fixed with a posterior plate (through the same incision). The lateral malleolus was addressed after fixation of the posterior malleolus, since a fibular plate would overlap the posterior malleolar fragment and hinders the judgment for reduction under image intensification. Syndesmotic injury was then assessed (after posterior and lateral malleolar fixation) with the hook test and a syndesmotic screw would be used if more than 2mm displacement occurred.

The medial malleolus was fixed last in cases of trimalleolar fractures while in the prone position, via standard medial approach, fixation is achieved using either two malleolar screws or tension band and wiring according to fragment size, lowering the operation table and knee in flexion when needed allows the medial malleolus to be addressed properly. Wound closure was done in layers, deep fascia with vicryl 2-0, followed by subcutaneous layer with 2-0 vicryl, skin closed with 2-0 prolene. Lightly compressive bulky dressing and splint were applied with the ankle in neutral position.

#### Post-operative follows up

Post-operative x-rays were performed after the patient has recovered from anesthesia (Figure 7).

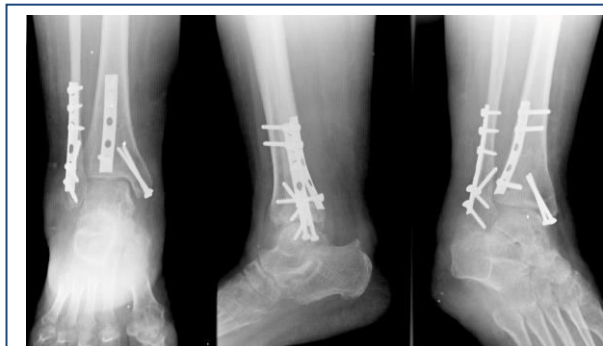

Figure 8: Follow-up X-rays.

When soft-tissue condition was suitable, cast immobilization was applied. Follow up was carried out in outpatient clinic, the first visit at two weeks post-operative for assessment of wound condition and suture removal, then monthly follow up over a period of 6-12 months (Figure 8), all patients were kept on non-weight bearing below knee cast for at least four weeks, then were progressed to weight bearing as tolerated in a walking cast for three weeks based on radiographic criteria,

then the cast was removed and full weight bearing was initiated.

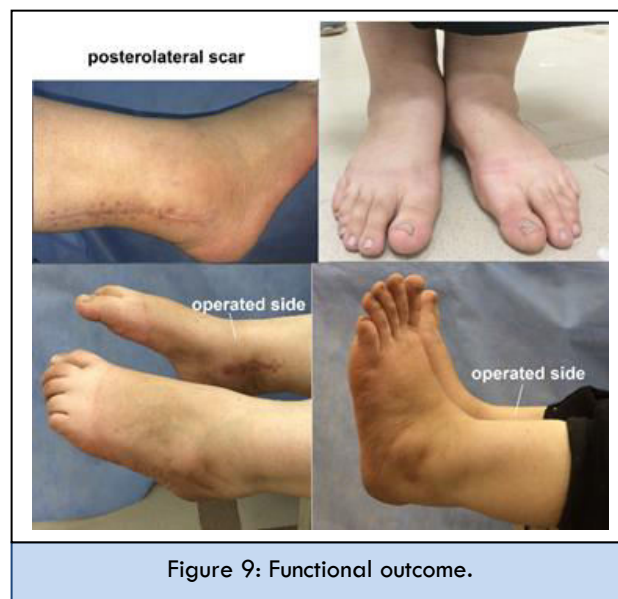

Figure 9: Functional outcome.

#### Methods for assessment of the results

Soft tissue complications were considered as any soft tissue event that required treatment, as antibiotic therapy, those requiring revision were considered major wound complications. Reduction was considered non-anatomical if articular step off >1mm on lateral radiographs. The fracture was considered united when at least 3/4 of the fracture line was healed on lateral radiographs and there was no tenderness at fracture site or on weight bearing. The functional outcome (Figure 9) of the cases was assessed by a modified Baird and Jackson scoring system [10-13] after at least six-month follow-up. This modification was done to fit the life style and usual activities of most of the Egyptian female patients (73.33% of this study), since the "ability to run" and "instability with sports" (as a part of the ankle stability score items) were not applicable questions (Table 1).

#### RESULTS

Follow up period ranged from 6 to 12 months with a mean of 8.46 months and standard deviation 1.75 months. According to the Baird and Jackson [10-13] scoring system for ankle fractures, the clinical results were graded with the Maximal Possible score being 100, however, after omitting the "ability to run" and "ankle stability", the maximal possible score was 75, with the excellent score being: 75-72, Good: 71-68, Fair: 67-60, and Poor: 59-0. Twelve patients achieved satisfactory results (five excellent, seven good) representing 80% of cases,



two cases (13.3%) had fair, and one (6.67%) had poor functional outcome based on the before-mentioned modified Baird and Jackson score.

**Table 1: The modified Baird and Jackson scoring system.**

Pain	score	Cases (n=15)
A. No pain	15	5
B. Mild pain with strenuous activity	12	9
C. Mild pain with activities of daily living	8	1
D. Pain on weight bearing	4	0
E. Pain at rest	0	0
<b>Ability to walk</b>		
A. Able to walk desired distances without limp or pain	15	10
B. Able to walk desired distances with limp or pain	12	5
C. Moderately restricted inability to walk	8	0
D. Able to walk short distances only	4	0
E. E. Unable to walk	0	0
<b>Ability to work</b>		
A. performs usual occupation without restrictions.	10	5
B. performs usual occupation with restrictions in some strenuous activities	8	9
C. Able to perform usual occupation with substantial restrictions	6	1
D. Partially disabled; selected jobs only.	3	0
E. Unable to work.	0	0
<b>Motion of the ankle</b>		
A. Within 10° of uninjured ankle	10	7
B. Within 15° of uninjured ankle	7	8
C. Within 20° of uninjured ankle	4	0
D. <50° of uninjured ankle or dorsiflexion < 5°	0	0
<b>Radiological</b>		
A. Anatomic with intact mortise (normal medial clear space, normal superior joint space, no talar tilt)	25	14
B. Same as A with mild reactive changes at the joint margins	15	1
C. Measurable narrowing of the superior joint space (2mm).	10	0
D. Moderate narrowing of the superior joint space between 2 and 1mm.	5	0
E. Severe narrowing of the superior joint space (<1mm)	0	0

There was adequate radiologic reduction of the posterior malleolus in all 15 patients with step off measured on lateral radiographs being less than 1 mm. There was no loss of reduction, no hardware loosening or irritation in all 15 cases. All fifteen patients had intact mortise. One patient had suboptimal reduction of the medial malleolus at the immediate postoperative x-rays; no revision was done to avoid risk of infection, particularly since the case was diabetic. However, the patient achieved good functional results at eight-month follow-up. One patient had early arthritic changes evident on

radiographs at seven-month follow up with subchondral sclerosis and narrowing of the superior joint space, but was still >2mm, with increasing pain, decreased range of motion, this case achieved poor functional outcome. Age, sex, and smoking had no influence on the final clinical outcome, nor did the mode of trauma and type of fracture. Posterior fragment size ranged from 20% to 45% with mean of 29.9% and standard deviation 7.8% however; fragment size had no statistical influence on the functional outcome. Diabetes (with six cases being Type 2) was found to have a significant influence on the final outcome (P value 0.049), mainly affecting the final range of ankle motion (P<0.05 statistically significant).

### Complications

Only one case developed erythema at wound edges a week after the operation and was managed by oral antibiotics and healed uneventfully. No deep infections or wound dehiscence developed in any of the cases. One patient (6.67%) had post-traumatic arthritis evident clinically and radiographically (but superior joint space was still >2mm). Two cases developed

Complex Regional Pain Syndrome (CRPS), which was observed after removal of the walking cast (after three months), they received treatment in the form of vitamin C, non-steroidal anti-inflammatory, and physiotherapy. They achieved some improvement at 6 months with decreased pain, edema and normalization of skin color. However, CRPS still had a statistically significant influence on the functional outcome, with P value 0.00182

### DISCUSSION

Fixation of the posterior malleolus is of great importance to the syndesmotic stability thus, careful anatomical reduction is important [14,15]. In this study, 80% achieved satisfactory results (five excellent and seven good), 13.3% had fair, and 6.67% had poor outcome based on the before-mentioned modification of the Baird and Jackson score. Using the American Orthopedic Foot and Ankle society (AOFAS) Ankle-hind foot scale [16], Choi JY et al [17] and Jia SH et al [18] reported a mean score of 90.6 and 92.0 respectively, Zhong S et al [19] had scores of 91.9 in the Posterolateral approach group. Ruo-kun H et al [20] using the Olerud-Molander Ankle Score (OMAS) reported 93.8% of good to excellent score, and although different assessment scores were used, they were

mostly satisfactory. In a retrospective study of 131 patients, Drijfhout van Hooff et al [21] had a Median AOFAS score of 90 (with good to excellent >75), while using the AAOS Questionnaire, score was 91. Hai-lin Xu et al [22] in a retrospective study that spanned 9 years and included 102 cases, the average AOFAS score was 95.9. However, some had less favorable results as Forberger J et al [23] are using the modified Weber protocol [24] for assessment and Choi JY et al [17] using the (OMAS) [25]. Fragment size was found to have no statistical influence on the functional outcome in our study, Drijfhout van Hooff et al [21] stated that fragment size didn't lead to a significantly lower function, but was associated with more incidence of osteoarthritis, which is also correlated to a step-off > 1mm postoperatively. Age and sex didn't have an influence on the outcome, neither did Smoking. Six patients (40%) had uncomplicated type 2 diabetes, which had a statistically significant influence on the functional outcome. Diabetics achieved lower scores in general, and particularly, in the final range of ankle motion. Most studies of posterior malleolar fractures didn't include diabetes as a factor in their study [3,20,26]. However, regarding ankle fractures in general, reports of similar results regarding the effect of diabetes were obtained by Egol KA et al [27], Soohoo NF et al [28], and Rao KN et al [29].

There were 6 cases of fractured posterior and lateral malleolus (Lauge- Hansen's SER 3) and nine cases trimalleolar fracture (Lauge-Hansen's SER 4). The type of fracture had no effect on the final functional outcome. All cases in this study had mainly a posterolateral fragment, being the classical posterior malleolar fracture. However, this approach was also described for a "posterior pilon" fracture, in which a combined axial and rotational forces result in a large, medially based fragment with possible comminution [4,30-32]. With only single large medially based fragment, posterolateral approach can be used alone, However, if more than two fragments, it may require additional medial or posteromedial approach, and if the fracture line exits anterior to the posterior colliculus, will always require a medial approach [30,31,33].

The sural nerve was encountered in five cases (33.33%). Amorosa LF et al [30] stated that the posterolateral incision doesn't normally intersect the sural nerve, being at risk when the incision is extended distal to the tip of fibula. None of the

cases had numbness in the sural nerve distribution postoperatively, however, Verhage S. M. et al [5] and Tornetta III P et al [34] had 3.8% and 5.5% of postoperative numbness in sural nerve distribution respectively, all cases had complete resolution.

All surgical wounds healed with no major complications, one case (6.6%) developed erythematous edges a week after the operation, which was managed only by oral antibiotics and dressings. Other authors found similar results [3,6,17,20,23,34]. In contrast, Tornetta III P et al [34] had 8.3% of cases developing superficial wound infection and 9.7% developing necrosis at wound edges, however, all healed with local wound care. Little MTM et al [26] had a postoperative infection rate of 4.4% (five out of 112), two were superficial requiring oral antibiotics only, and three were deep requiring debridement, hardware was removed in two cases after union due to deep seated infection. Hoiness P et al [35] and Kumar R MC et al [36] evaluate ankle fractures as a whole through standard lateral approach. reported an over-all wound complication rate of 22% and 17.7% respectively, which shows that the infection rate in posterolateral approach is not more, but maybe less than that reported for ankle fractures in general using standard approaches, which is probably a result of adequate soft tissue coverage, and the rarity of bruises and edema on posterolateral aspect.

None of the included cases required syndesmotic screws, and all were stable intraoperatively with the hook test following posterior and lateral malleolar fixation. Verhage S. M. et al [5] had 96% of cases showing stability of syndesmosis after fixation of posterior malleolus, and only two cases requiring syndesmotic screw. Gardner MJ et al [37] performed biomechanical investigations and showed that posterior malleolar fixation resulted in syndesmotic stiffness that was 70% of the intact model, compared with only 40% with syndesmotic screw. Many authors stated that anatomical reduction of posterior malleolus was superior to syndesmotic screws, decreasing the possibility of malreduction, and the need for a subsequent surgery for removal [37-39]. seven patients (46.67%) achieved near normal range of ankle motion, with less than 10 degrees difference compared to the non-operated side, while eight patients (53.3%) had 10-15 degrees loss of range of motion compared to normal side, this

is less than the results reported by other authors [6,23,34,40]. We believe this to be a result of non-compliance of our patients with physiotherapy and also the long casting duration, as patients in this study were kept in a non-weight bearing cast for four to five weeks, then a weight bearing cast for three weeks. Most studies implemented non-weight bearing for 6 weeks [5,6,31], however, cast duration was two to four weeks, unless stability was in question [5,33,41]. One case (6.67%) developed post-traumatic arthritis, and most literature report this complication in less than 8% of case [5,26,42] Von Rüden C et al [43] reported less severe post-traumatic arthritis in the ORIF group with posterolateral approach compared to indirect AP screw group. We had two cases (13.3%) showing evidence of CRPS, A study of 72 cases by Tornetta III P et al [34] didn't report the occurrence of CRPS, and Forberger J et al [23] in a study of 52 patients, had only two cases. that probably due to increased period of casting in our group. No cases developed delayed or non-union, as reported by many authors [3,20,34].

All cases were operated in the prone position, and although awkward at first, medial malleolar fixation in prone position was not difficult, which was also reported by Abdelgawad AA et al [3] we had only one case of suboptimal reduction of medial malleolus, no revision was done and the patient achieve good functional outcome. The posterior malleolus was fixed first, to allow assessment of the articular surface post reduction using image intensification without being hindered by the lateral plate. Dhillon MS et al [44] used the same order of fixation, which is also the order recommended in Rockwood and Green text book [14].

CT scans were not obtained following the operations, post-operative assessment and follow up was limited to plain radiographs, as did many other authors [3,5,6,26,42,45]. None of the cases had residual articular step off, or loss of reduction on follow-up visits, Tornetta III P et al [26], and Little MTM et al [26] had similar results. In contrast, Abdelgawad AA et al [3] and Erdem et al [6] had loss of reduction of 2mm in 8.3% and 5% in those plated by posterolateral approach respectively.

### LIMITATIONS OF THE STUDY

- Small sample size
- Lack of an Arabic (or Egyptian) scoring system for assessment of ankle function that fits the life style of most of our population.

- Noncompliance of the patients with physiotherapy due to financial causes and limited availability in remote areas.

### CONCLUSION

Plate fixation of posterior malleolus through posterolateral approach is an alternative to indirect reduction and anterior to posterior screw fixation, with minimal complications, while adding the advantage of direct visualization of the fragment and rigid fixation.

### REFERENCES

1. Tenenbaum S, Shazar N, Bruck N, Bariteau J. (2017). Posterior Malleolus Fractures. *Orthop Clin North Am.* 48: 81-89.
2. Ogilvie-Harris DJ, Reed SC, Hedman TP. (1994). Disruption of the ankle syndesmosis: biomechanical study of the ligamentous restraints. *Arthrosc J Arthrosc Relat Surg.* 10: 558-560.
3. Abdelgawad AA, Kadous A, Kanlic E. (2011). Posterolateral Approach for Treatment of Posterior Malleolus Fracture of the Ankle. *J Foot Ankle Surg.* 50: 607-611.
4. Chen DW, Li B, Aubeeluck A, Yang YF, Zhou JQ, et al. (2014). Open reduction and internal fixation of posterior pilon fractures with buttress plate. *Acta Ortopédica Bras.* 22: 48-53.
5. Verhage SM, Boot F, Schipper IB, Hoogendoorn JM. (2016). Open reduction and internal fixation of posterior malleolar fractures using the posterolateral approach. *Bone Joint J.* 98-B: 812-817.
6. Erdem MN, Erken HY, Burc H, Saka G, Korkmaz MF, et al. (2014). Comparison of lag screw versus buttress plate fixation of posterior malleolar fractures. *Foot Ankle Int.* 35:1022-1030.
7. Lauge-Hansen N. (1950). Fractures of the ankle. II. Combined experimental-surgical and experimental-roentgenologic investigations. *Arch Surg.* 60: 957-985.
8. Gustilo RB, Anderson JT. (1976). Prevention of infection in the treatment of one thousand and twenty-five open fractures of long bones: retrospective and prospective analyses. *Bone Jt Surg.* 58: 453-458.
9. Hoppenfield S, de Boer P, Buckley R. (2009). Surgical Exposures in Orthopaedics: the anatomic approach. 92-B: 186-186.

10. Baird RA, Jackson ST. (1987). Fractures of the distal part of the fibula with associated disruption of the deltoid ligament. Treatment without repair of the deltoid ligament. *J Bone Joint Surg Am.* 69: 1346-1352.
11. Jhatoth DS. (2017). Evaluation and surgical management of bimalleolar fractures of ankle joint. 3: 620-623.
12. Badgire K, Rajiv Mario Colaco, Naik Lokesh Gudda G, Waybase Ashok Hanumant, Sharma Gaurav Mahesh, et al. (2017). Functional outcome of surgical management of malleolar fractures of the ankle joint using Baird- Jackson scoring - A Prospective study. *Int J Med Heal Res.* 3: 42-45.
13. Shekhar DV. (2017). Outcome of Surgical Management of Bimalleolar Fractures - our Experience. *IOSR J Dent Med Sci.* 16: 34-37.
14. Court-Brown C, Heckman JD, McQueen MM, Ricci W, Tornetta P III MM. (2015). Rockwood and Green's Fractures in Adults. In 8<sup>th</sup> edn, Wolters Kluwer. 2541-2592.
15. Rüedi TP, Murphy WM. (2001). AO principles of fracture management. In: Davos: AO Publishing & Stuttgart New York: Georg Thieme Verlag. Vol 2 2<sup>nd</sup> edn. 870-896.
16. Kitaoka HB, Alexander IJ, Adelaar RS, Nunley JA, Myerson MS, et al (1994). Clinical rating systems for the ankle-hindfoot, midfoot, hallux, and lesser toes. *Foot ankle Int.* 15: 349-353.
17. Choi JY, Kim JH, Ko HT, Suh JS. (2015). Single Oblique Posterolateral Approach for Open Reduction and Internal Fixation of Posterior Malleolar Fractures With an Associated Lateral Malleolar Fracture. *J Foot Ankle Surg.* 54: 559-564.
18. Jia SH, Huang CL, Xu HW, Gong SL. (2016). Surgical treatment for posterior Pilon fracture through posterolateral approach. *China J Orthop Traumatol.* 29: 557-560.
19. Zhong S, Shen L, Zhao J, Chen J, Xie J, et al. (2017). Comparison of posteromedial versus posterolateral approach for posterior malleolus fixation in trimalleolar ankle fractures. *Orthop Surg.* 9: 69-76.
20. Ruo-kun H, Ming X, Jing-jing Z, Kai X, Wu-sheng K. (2012). Posterior malleolar fracture: Technique and clinical experience of the posterolateral approach. *Chin J Traumatol.* 15: 23.
21. Van Hooff CCD, Verhage SM, Hoogendoorn JM. (2015). Influence of fragment -26. size and postoperative joint congruency on long-term outcome of posterior malleolar fractures. *Foot Ankle Int.* 36: 673-678.
22. Xu HL, Li X, Zhang DY, Fu ZG, Wang TB, et al. (2012). A retrospective study of posterior malleolus fractures. *Int Orthop.* 36: 1929-1936.
23. Forberger J, Sabandal PV, Dietrich M, Gralla J, Lattmann T, et al. (2009). Posterolateral Approach to the Displaced Posterior Malleolus: Functional Outcome and Local Morbidity. *Foot Ankle Int.* 30: 309-314.
24. Marti RK, Raaymakers EL, Nolte PA. (1990). Malunited ankle fractures. The late results of reconstruction. *J bone Jt Surg Br Vol.* 72: 709-713.
25. Olerud C, Molander H. (1984). A scoring scale for symptom evaluation after ankle fracture. *Arch Orthop Trauma Surg.* 103: 190-194.
26. Tornetta P III, Ricci W, Nork S, Collinge C, Steen B. (2011). The posterolateral approach to the tibia for displaced posterior malleolar injuries. *J Orthop Trauma.* 25: 123-126.
27. Egol KA, Tejwani NC, Walsh MG, Capla EL, Koval KJ. (2006). Predictors of short-term functional outcome following ankle fracture surgery. *J Bone Jt Surg Am.* 88: 974-979.
28. SooHoo NF, Krenke L, Eagan MJ, Gurbani B, Ko CY, et al. (2009). Complication rates following open reduction and internal fixation of ankle fractures. *J Bone Jt Surg - Ser A.* 91: 1042-1049.
29. Rao KN, KS AH, Sekhar PC, Krishna CV. (2017). Functional outcome and complications of surgically managed malleolar fractures at ankle. 3: 770-774.
30. Amorosa LF, Brown GD, Greisberg J. (2010). A Surgical Approach to Posterior Pilon Fractures. *J Orthop Trauma.* 24: 188-193.
31. Klammer G, Kadakia AR, Joos DA, Seybold JD, Espinosa N. (2013). Posterior pilon fractures: a retrospective case series and proposed classification system. *Foot ankle Int.* 34:189-199.



32. Switaj PJ, Weatherford B, Fuchs D, Rosenthal B, Pang E, et al. (2014). Evaluation of posterior malleolar fractures and the posterior pilon variant in operatively treated ankle fractures. *Foot ankle Int.* 35: 886-895.
33. Huber M, Stutz PM, Gerber C. (1996). Open reduction and internal fixation of the posterior malleolus with a posterior antiglide plate using a postero-lateral approach-a preliminary report. *Foot Ankle Surg.* 2: 95-103.
34. Little MTM, Berkes MB, Lazaro LE, Sculco PK, Helfet DL, et al. (2013). Complications following treatment of supination external rotation ankle fractures through the posterolateral approach. *Foot ankle Int.* 34: 523-529.
35. Hoiness P, Engebretsen L, Stromsoe K. (2001). The influence of perioperative soft tissue complication on the clinical outcome in surgically treated ankle fractures. *Foot Ankle Int.* 22: 642-648.
36. Kumar MCR, Vivian RD' Almedia, Thomas Babu A, Terence D' Souza. (2017). To assess the clinical outcome of ankle fractures with regards to the demographic variables and the quality of reduction of the fractures. *Int J Orthop Sci.* 3: 445-448.
37. Gardner MJ, Brodsky A, Briggs SM, Nielson JH, Lorch DG. (2006). Fixation of posterior malleolar fractures provides greater syndesmotic stability. *Clin Orthop Relat Res.* 447: 165-171.
38. Benthien RA. (2014). The posterolateral approach to the posterior malleolus: An alternative surgical strategy for unstable trimalleolar ankle fractures. *Tech Orthop.* 29: 8-12.
39. Miller AN, Carroll EA, Parker RJ, Helfet DL, Lorch DG. (2010). Posterior Malleolar Stabilization of Syndesmotic Injuries is Equivalent to Screw Fixation. *Clin Orthop Relat Res.* 468: 1129-1135.
40. Shi H, Xiong J, Chen Y, Wang J, Qiu X-S, et al. (2017). Comparison of the direct and indirect reduction techniques during the surgical management of posterior malleolar fractures. *BMC Musculoskelet Disord.* 18: 109.
41. Mingo-Robinet J, López-Durán L, Galeote JE, Martínez-Cervell C. (2011). Ankle fractures with posterior malleolar fragment: Management and results. *J Foot Ankle Surg.* 50: 141-145.
42. Ruokun H, Ming X, Zhihong X, Zhenhua F, Jingjing Z, et al. (2014). Postoperative radiographic and clinical assessment of the treatment of posterior tibial plafond fractures using a posterior lateral incisional approach. *J Foot Ankle Surg.* 53: 678-682.
43. Von Rüden C, Hackl S, Woltmann A, Friederichs J, Bühren V, et al. (2015). Posterolateral Approach - an alternative to closed anterior-posterior screw osteosynthesis in complex ankle fractures. *Z Orthop Unfall.* 153: 289-295.
44. Dhillon MS, Dureja K, Patel S, Bansal T. (2017). How we do it. Trimalleolar Fractures : Fixing the Posterior Malleolus by Posterolateral Approach. *J Foot Ankle Surg (Asia-Pacific).* 4: 63-68.
45. O'Connor TJ, Mueller B, Ly TV, Jacobson AR, Nelson ER, et al. (2015). "A to P" screw versus posterolateral plate for posterior malleolus fixation in trimalleolar ankle fractures. *J Orthop Trauma.* 29: 151-156.