

Endoscopic Posterior Nasal Neurectomy with Continuous-Suction Irrigation Method

Takeo Kanaya^{1*} and Naoyuki Kohno²

¹Chief Physician, Otorhinolaryngology, Kosei Hospital, Japan

²Otorhinolaryngology, Kyorin University Hospital, Japan

ARTICLE INFO

Article history:

Received: 23 June 2017

Accepted: 07 September 2017

Published: 15 September 2017

Keywords:

Endoscopic;
Posterior nasal nerve;
Posterior nasal neurectomy;
Inferior turbinoplasty;
Suction; Irrigation;
Vasomotor rhinitis;
Perennial rhinitis;
Chronic rhinitis

Copyright: © 2017 Kanaya T et al.,
J Otolaryngol Res

This is an open access article distributed under the Creative Commons Attribution License, which permits unrestricted use, distribution, and reproduction in any medium, provided the original work is properly cited.

Citation this article: Kanaya T, Kohno N. Endoscopic Posterior Nasal Neurectomy with Continuous-Suction Irrigation Method. J Otolaryngol Res. 2017; 1(1):113.

Correspondence:

Takeo Kanaya,
Department of
Otorhinolaryngology, Kosei
Hospital, 2-9-2-211, Oosaki,
Shinagawa-ku, Tokyo 141-0032,
Japan; Tel: +819015525842;
Email: takeokyorin@yahoo.co.jp

ABSTRACT

Background: Endoscopic posterior nasal neurectomy was developed in 1997.

This surgery is often performed to reduce rhinorrhea and sneezing in patients with chronic rhinitis. The original technique involves resection of the posterior superior lateral nasal nerves at the sphenopalatine foramen. However, it is difficult to selectively resect only the nerves without injuring the blood vessels using this technique. As a result, several modified surgical procedures have been developed. Simultaneous resection of the nerves and blood vessels using a harmonic scalpel at the sphenopalatine foramen is the easiest procedure, but it is associated with a possibility of severe intraoperative or postoperative epistaxis. Resection of the peripheral nerves of the posterior nasal nerves in the inferior turbinate is a recently developed alternative to original endoscopic posterior nasal neurectomy, but inferior turbinoplasty is necessary to resect the peripheral nerves. Therefore, this method should be unused for patients with no nasal obstruction. We developed a continuous-suction irrigation method for endoscopic nasal surgery in narrow surgical spaces. This method can clarify the surgical view resembling an underwater environment. It enables the surgeon to selectively resect the posterior superior lateral nasal nerves. We herein describe the performance of endoscopic posterior nasal neurectomy with our new method.

Method: Endoscopic posterior nasal neurectomy was performed bilaterally for forty-three patients who have perennial rhinitis under general anesthesia. An irrigation-suction straw sheath system was used to create a fine surgical view resembling an underwater environment.

Results: We performed endoscopic posterior nasal neurectomy with a continuous-suction irrigation method in forty-three patients from January 2016 to May 2017 in Kosei Hospital, Japan. The posterior superior lateral nasal nerves were selectively resected in all patients. No severe complications occurred after surgery. Reduced subjective rhinorrhea and sneezing were observed after surgery in all cases.

Conclusions: The posterior superior lateral nasal nerves can be safely resected using this technique without any complications. We believe that the original endoscopic posterior nasal neurectomy can be performed easily and safely using our new method.

Abbreviations: EPNN: Endoscopic Posterior Nasal Neurectomy; SPF: Sphenopalatine Foramen; PNN: Posterior Nasal Nerves; SPA: Sphenopalatine Artery; PSLNN: Posterior Superior Lateral Nasal Nerves

Introduction

Endoscopic posterior nasal neurectomy (EPNN) was developed as an alternative to vidian neurectomy in 1997 [1]. EPNN involves resection of the posterior nasal nerves at the Sphenopalatine Foramen (SPF) under direct vision. The Posterior Nasal Nerves (PNN) arise from the vidian nerve and include the parasympathetic nerve fibers and the trigeminal nerve fibers. Therefore, resection of the PNN can reduce rhinorrhea and sneezing.

Particularly in Japan, EPNN is actively performed not only for vasomotor rhinitis but also perennial rhinitis, which is resistant to conservative medical treatment. Several surgical techniques for EPNN have been reported [1-3]. The original technique involves resection of the PNN at the SPF via the middle nasal meatus. Surgeons must manipulate around the Sphenopalatine Artery (SPA) to resect the Posterior Superior Lateral Nasal Nerves (PSLNN) without injuring the SPA in a narrow surgical field. Therefore, the original technique is difficult even if a surgeon has advanced endoscopic nasal surgery skills.

Resection of the peripheral nerves from the PNN in the inferior turbinate recently becomes an alternative to the original EPNN in Japan [2]. This technique is useful and effective to reduce nasal drip, but turbinoplasty is necessary to cut the peripheral nerves. We often encounter patients whose chief complaint is only rhinorrhea. Only PNN should be recommended to such patients.

We developed a new surgical technique called the continuous-suction irrigation method to obtain a clear surgical view and perform fine manipulations in narrow spaces [4]. This method allows the surgeon to create a fine surgical view resembling an underwater environment. We can easily resect the PSLNN while preserving both the SPA and veins using this method. We performed EPNN with this method in forty-three patients

from January 2016 to May 2017 in Kosei Hospital, Japan. No severe postoperative complications occurred. We herein describe the performance of the original EPNN with our new continuous-suction irrigation method.

Materials and Methods

1. Subjects

Forty-three patients, 25 males and 18 females (age range 15 to 73 years, median age 38 years) with perennial rhinitis which is resistant to conservative medical therapies and operated on at Kosei Hospital, Japan, were included. The following procedures were performed: only EPNN in 3 cases; EPNN with turbinoplasty in 5 cases; EPNN with endoscopic sinus surgery in 4 cases; EPNN with septoplasty and turbinoplasty in 26 cases; EPNN with septoplasty, turbinoplasty and endoscopic sinus surgery in 5 cases. EPNN, turbinoplasty and endoscopic sinus surgery were performed bilaterally in all cases.

2. Irrigation-suction straw sheath system

The use of an irrigation-suction straw sheath system (K-Endosheath; Koken Co., Tokyo, Japan) is important to create a fine surgical view resembling an underwater environment [5]. This device has two important parts: a main body and a disposable straw (Figure 1). A suction tube and water supply tube are connected to the main body. A push button on the main body is pressed to supply water to the disposable straw. It is pressed continuously during surgery. A 14-Fr Nelaton catheter (Nipro Corp., Osaka, Japan) is inserted into the opposite side of the nasal cavity to absorb water at the nasopharynx.

3. Preparation

The operation is performed under general anesthesia using a 4-mm 0-degree endoscope. The surgeon sits on the patient's right side, facing the monitor. Gauze soaked in 1:2000 epinephrine is used to shrink the nasal mucosa, and 1:100,000 epinephrine is injected at the posterior part of the middle nasal meatus.

4. Surgical technique

A vertical incision is made on the membranous portion of the maxillary sinus (Figure 2). There are no thick arteries in the membranous portion; therefore, the risk of arterial

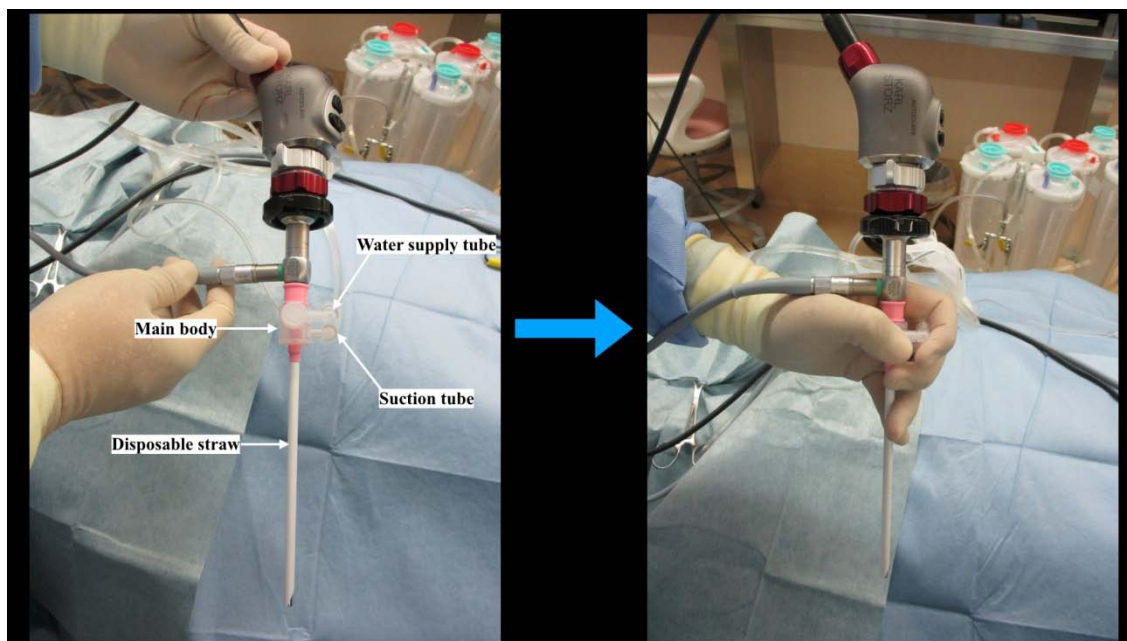


Figure 1: The irrigation-suction straw sheath system consists of four parts: main body, disposable straw, water supply tube, and suction tube.

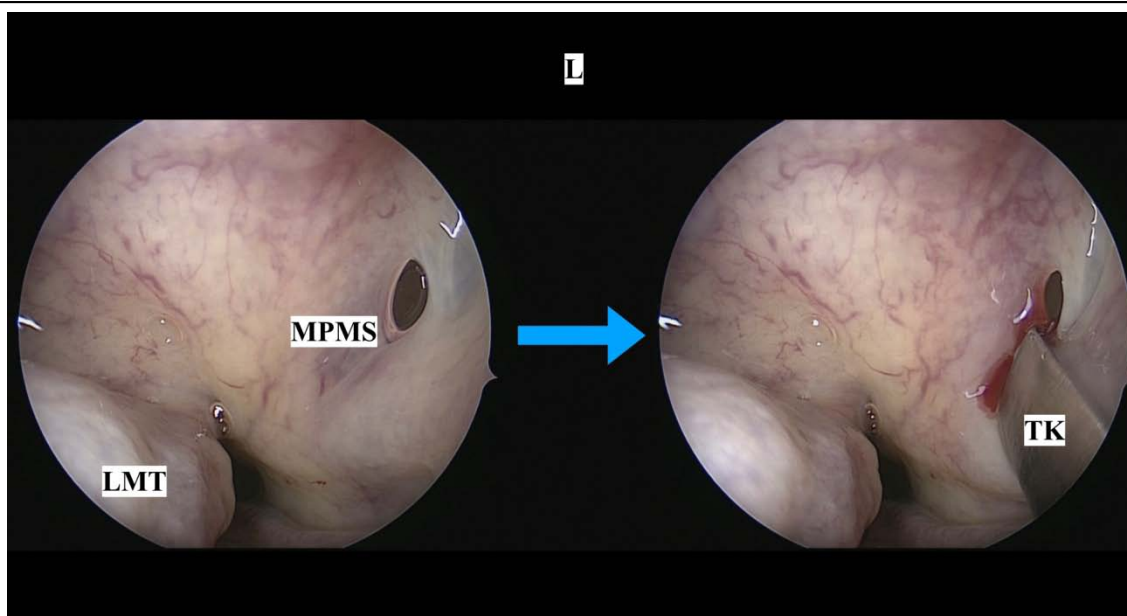


Figure 2: A vertical incision is made on the membranous portion of the maxillary sinus.
L: Left; LMT: Left Middle Turbinate; MPMS: Membranous Portion of the Maxillary Sinus; TK: Triangle Knife

hemorrhage is low. The 0-degree endoscope is inserted into the maxillary sinus. The perpendicular plate of the palatine bone is confirmed. The mucoperiosteal flap is elevated from the anterior part of the perpendicular plate of the palatine bone to the level of the SPF (Figure 3). A continuous water supply is begun using the irrigation-suction straw sheath system. The mucoperiosteum around the SPA is separated with a bipolar coagulation forceps (Muranaka Medical Instruments Co., Ltd., Osaka, Japan). The PSLNN, SPA,

and veins are confirmed (Figure 4). PSLNN are resected and coagulated with the bipolar coagulation forceps (Figure 5). The SPA and veins are preserved. Finally, the mucoperiosteal flap is put back to its initial position. A nasal tampon is not necessary.

Results

The PSLNN were resected without injuring the SPA in all cases. No complications occurred, including severe intraoperative or postoperative epistaxis, adhesion,

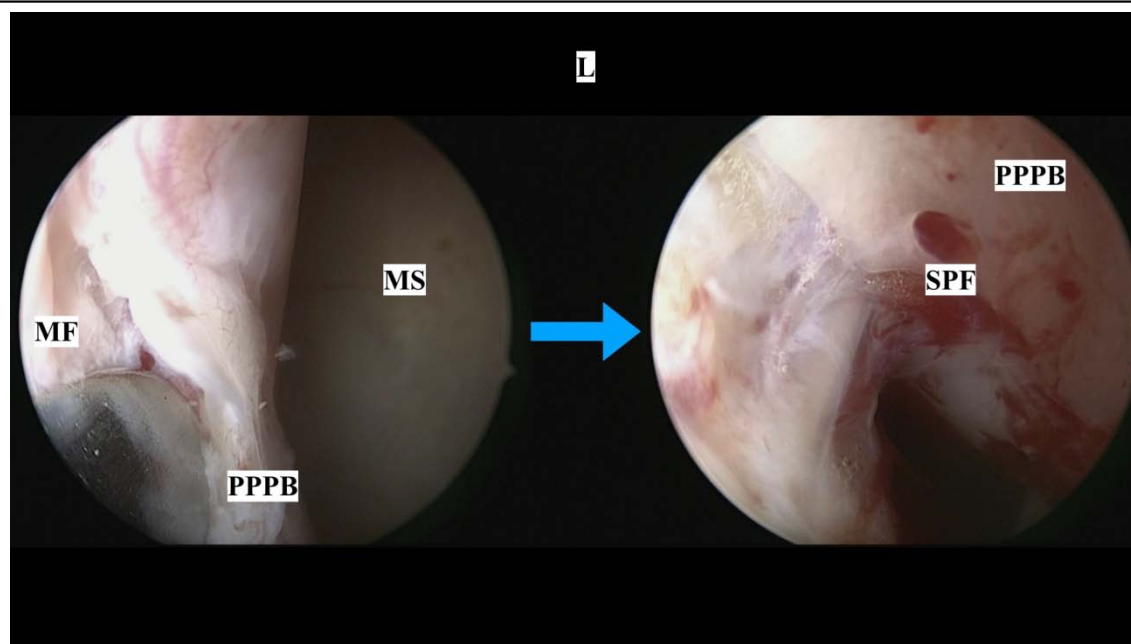

Figure 3: The mucoperiosteal flap is elevated from the anterior part of the perpendicular plate of the palatine bone to the level of the sphenopalatine foramen.

L: Left; MF: Mucoperiosteal Flap; MS: Maxillary Sinus; PPPB: Perpendicular Plate of the Palatine Bone; SPF: Sphenopalatine Foramen

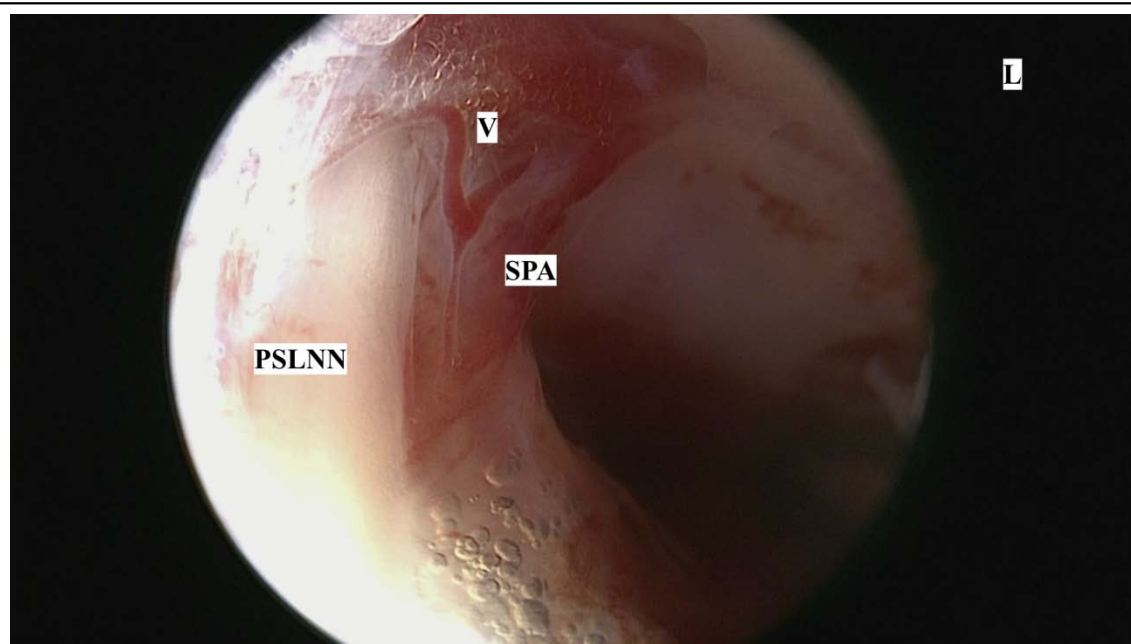


Figure 4: The posterior superior lateral nasal nerves, sphenopalatine artery, and veins are confirmed.

L: Left; PSLNN: Posterior Superior Lateral Nasal Nerves; SPA: Sphenopalatine Artery; V: Veins

paresis and impaired tears secretion. Reduced subjective rhinorrhea and sneezing were confirmed by a medical interview (no scoring) after surgery in all cases.

Discussion

Several surgical techniques for resecting the PNN have been reported. Cutting the PNN and SPA simultaneously using a harmonic scalpel at the SPF is the easiest method

[3]. However, it may cause severe intraoperative or postoperative epistaxis. Therefore, we do not recommend this procedure from a safety standpoint.

Resection of the peripheral nerves of the PNN in the inferior turbinate is mainly performed as an alternative to the original EPNN [2]. This method has a treatment effect nearly equal to that of the original EPNN. It is an easier and safer technique, but submucosal inferior

turbinoplasty is necessary. It might not be indicated for patients who have only rhinorrhea. We believe that resection of the PSLNN at a more central portion would be more optimal if surgeon could safely resect the PSLNN at the SPF. In theory, the effect of resecting the PSLNN at the SPF would be broader than the effect of resecting the peripheral nerves of the PNN in the inferior turbinate.

The difficulty of selectively resecting the PSLNN without injuring the SPA was the main reason for developing alternative EPNN techniques. However, if surgeons use the continuous-suction irrigation method, they can readily confirm and resect only the PSLNN under a clear direct view while preserving the blood vessels. The continuous water flow flushes the blood from the surgical field and causes the color of the tissue at the SPF to become more vivid (Figure 6A, B).

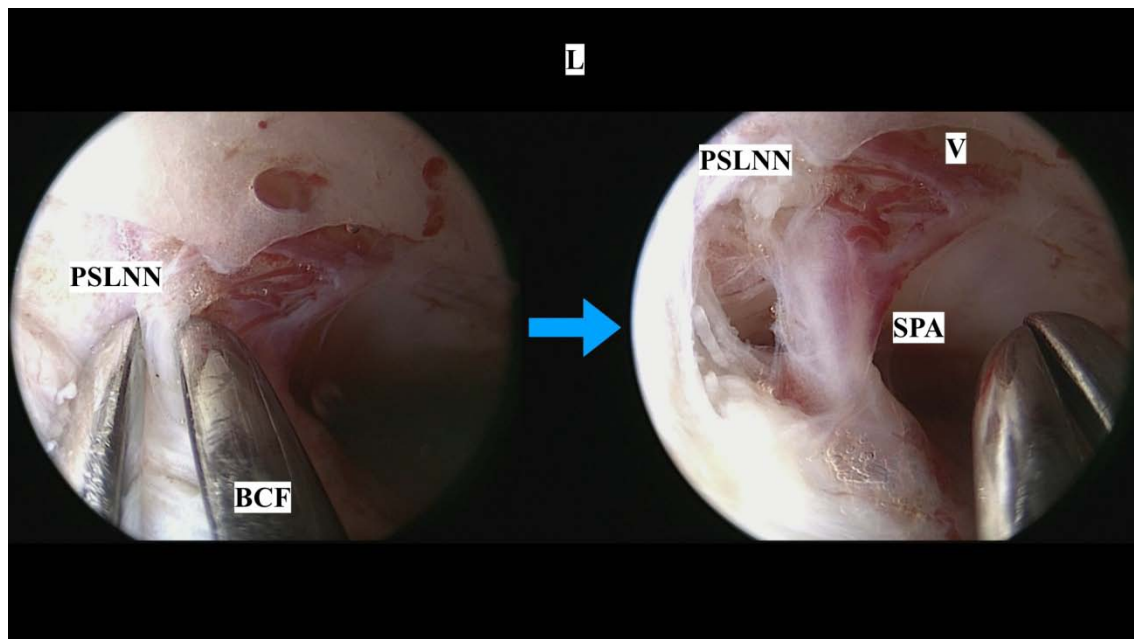


Figure 5: The posterior superior lateral nasal nerves are resected and coagulated with bipolar coagulation forceps.

L: Left; PSLNN: Posterior Superior Lateral Nasal Nerves; BCF: Bipolar Coagulation Forceps; SPA: Sphenopalatine Artery; V: Veins

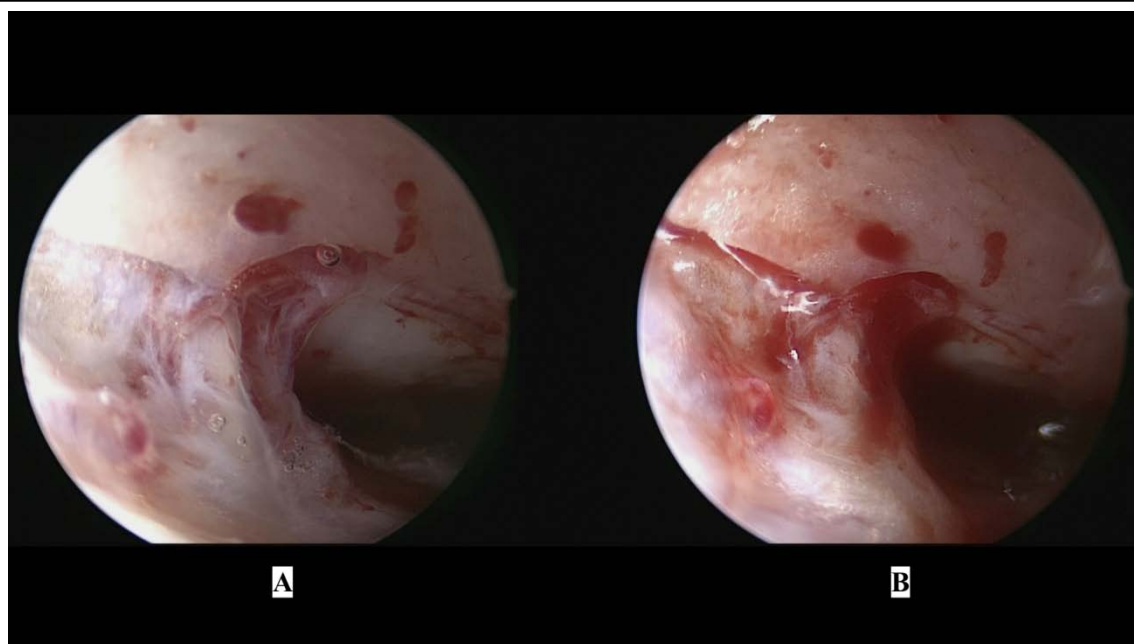

Figure 6: Comparison between endoscopic posterior nasal neurectomy (A) with and (B) without water flow.

This method makes the original EPNN easier to perform. In addition, selective resection of the PSLNN can reduce the risk of intraoperative and postoperative epistaxis. However, this method has several limitations. First, surgeons are required to have advanced nasal endoscopic surgery skills. They are forced to perform fine manipulations within a narrow surgical field and place the endoscope as close to the SPF as possible to obtain a surgical view resembling an underwater environment. Second, it is difficult to approach the SPF via the middle meatus if a patient has severe septal deviation. Skillful surgeon is able to perform EPNN without septoplasty. However, inexperienced surgeon had better perform septoplasty before doing EPNN. If EPNN is done without septoplasty, approaching the SPF via the inferior meatus or inside of the inferior turbinate are feasible options. EPNN via the inferior meatus or inside of the inferior turbinate are superior in terms of atraumatic technique to the common nasal meatus, but the distance to the SPF is longer than EPNN via the middle meatus. Though, these techniques might be challenging surgery for inexperienced surgeons.

The purpose of this article is describing our surgical technique for EPNN, therefore evaluation of the effectiveness of EPNN alone is not sufficient. We think that proper evaluation for EPNN alone is necessary.

Conclusion

We developed the continuous-suction irrigation method to obtain a fine surgical view in narrow and bloody spaces. This technique enables surgeons to selectively resect the PSLNN without injuring the blood vessels under a clear surgical view resembling an underwater environment. This method is useful not only for EPNN but also for other endoscopic nasal surgeries.

References

1. Toru Kikawada. (2007). Endoscopic posterior nasal neurectomy: An alternative to vidian neurectomy. *Operative Techniques in Otolaryngology*. 18: 297-301.
2. Kobayashi T, Hyodo M, Nakamura K, Komobuchi H, Honda N. (2012). Resection of peripheral branches of the posterior nasal nerve compared to conventional posterior neurectomy in severe allergic rhinitis. *Auris Nasus Larynx*. 39: 593-596.
3. Ikeda K, Oshima T, Suzuki M, Suzuki H, Shimomura A. (2006). Functional inferior turbinate surgery (FITS) for the treatment of resistant chronic rhinitis. *Acta Otolaryngol*. 126: 739-745.
4. Kanaya T, Kohno N. (2017). Submucosal Inferior Turbinoplasty Using a New Continuous Suction Irrigation Method. *Front Surg*. 4: 24.
5. Kubo S, Kikawada T, Hasegawa H, Tominaga S, Yoshimine T. (2005). Irrigation-Suction Straw Sheath System for a Rigid Endoscope during Endonasal Endoscopic Pituitary Surgery. *Minim Invasive Neurosurg*. 48: 373-375.